

REVIEW ARTICLE

MEDICAL PROGRESS

Williams–Beuren Syndrome

Barbara R. Pober, M.D.

WILLIAMS–BEUREN SYNDROME (ALSO KNOWN AS WILLIAMS’ SYNDROME; Online Mendelian Inheritance in Man [OMIM] number, 194050), a multi-system disorder, is caused by deletion of the Williams–Beuren syndrome chromosome region, spanning 1.5 million to 1.8 million base pairs and containing 26 to 28 genes. Exactly how gene loss leads to the characteristic phenotype of Williams–Beuren syndrome is unknown, but hypoeexpression of gene products is likely to be involved. Estimated to occur in approximately 1 in 10,000 persons,¹ Williams–Beuren syndrome is a microdeletion disorder, or contiguous-gene-deletion disorder, that can serve as a model for the study of genotype–phenotype correlations and potentially reveal genes contributing to diabetes, hypertension, and anxiety.

The first cases of Williams–Beuren syndrome were described as two seemingly unrelated disorders. One presentation was characterized by hypercalcemia plus persistent growth failure, characteristic facial appearance, “mental retardation,” heart murmur, and hypertension,^{2,3} while the other was characterized by supravalvular aortic stenosis (narrowing of the ascending aorta above the aortic valve, involving the sinotubular junction) plus a distinctive facial appearance, “mental retardation,” “friendly” personality, and growth retardation.^{4,5} Subsequent description of a patient with features common to both phenotypes indicated that these were variations of the same disorder,⁶ now referred to as Williams–Beuren syndrome.

CAUSES AND CURRENT DIAGNOSTIC TESTS

Vitamin D teratogenicity was first considered as the cause of Williams–Beuren syndrome, on the basis of experiments showing supravalvular aortic stenosis and craniofacial abnormalities in rabbit fetuses exposed to high-dose vitamin D.^{7,8} Two compelling lines of evidence later showed that Williams–Beuren syndrome was genetic, not teratogenic: transmission of Williams–Beuren syndrome from parent to child^{9,10} and characterization of the phenotypically overlapping autosomal dominant familial supravalvular aortic stenosis syndrome (OMIM number, 185500). Familial supravalvular aortic stenosis, which is caused by disruption of the elastin gene (*ELN*), is associated with cardiovascular abnormalities that are characteristic of Williams–Beuren syndrome but with few of the syndrome’s other features.^{11,12} The screening of patients with Williams–Beuren syndrome for *ELN* mutations revealed none; rather, one *ELN* allele was completely lacking, suggesting that Williams–Beuren syndrome was a microdeletion disorder, not a point-mutation disorder.¹³

Recognition of Williams–Beuren syndrome usually starts with the astute clinician. Clinical diagnostic criteria^{14,15} have only modest usefulness as compared with rapid and accurate laboratory testing. Fluorescence in situ hybridization (FISH) involving *ELN*-specific probes establishes the diagnosis of Williams–Beuren syndrome by showing the presence of a single *ELN* allele only rather than two alleles (Fig. 1A). Although FISH remains the most widely used laboratory test, the diagnosis can also be established by means of microsatellite marker analysis, multiplex ligation-

From the Center for Human Genetics, Massachusetts General Hospital, Boston. Address reprint requests to Dr. Pober at the Center for Human Genetics, Simches Research Bldg., 185 Cambridge St., Boston, MA 02114, or at pober.barbara@mgh.harvard.edu.

N Engl J Med 2010;362:239-52.

Copyright © 2010 Massachusetts Medical Society.

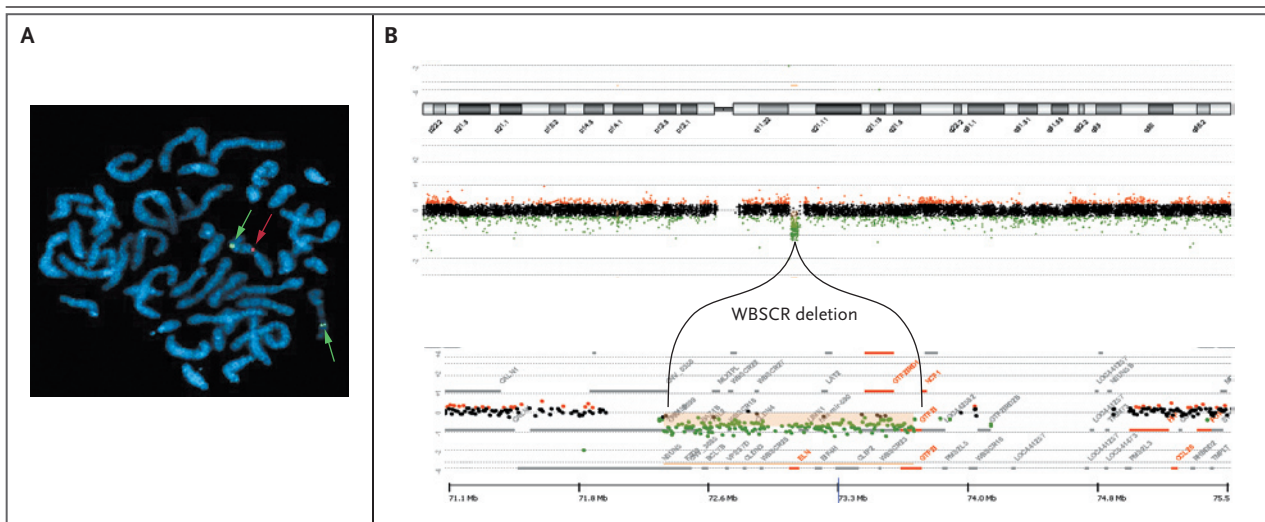


Figure 1. Common Laboratory Methods for Diagnosing Williams–Beuren Syndrome.

In patients with Williams–Beuren syndrome, fluorescence in situ hybridization (Panel A) reveals a normal, nondeleted chromosome 7 — with two hybridization signals, one of which confirms the presence of the elastin gene (*ELN*) (red arrow) and the second, the presence of a chromosome 7–specific control gene (adjacent green arrow) — and a deleted chromosome 7, which shows the control hybridization signal only (green arrow, lower right), indicating that *ELN* is deleted. The results of array comparative genomic hybridization are shown on a schematic of chromosome 7 (Panel B, top; from an Agilent 244K microarray), revealing the loss of one copy of the Williams–Beuren syndrome chromosome region (WBSCR), approximately 1.5 Mb in size, as indicated by the cluster of green hybridization signals (Panel B, middle). An enlarged view of the WBSCR is also shown (Panel B, bottom). See Figure 3A and the Supplementary Appendix, available with the full text of this article at NEJM.org, for additional details about the genes within the WBSCR.

dependent probe amplification, quantitative polymerase-chain-reaction assay, or array comparative genomic hybridization (Fig. 1B). Though not yet cost-competitive, array comparative genomic hybridization offers advantages if the clinical impression is not clearly consistent with Williams–Beuren syndrome or if the patient has an “atypical” deletion, since this method can delineate the deleted genes.

COMMON CLINICAL FEATURES

Williams–Beuren syndrome has a characteristic constellation of findings. The facial features range from subtle to dramatic (Fig. 2). Young children are often described as cute or pixielike, with a flat nasal bridge, short upturned nose, periorbital puffiness, long philtrum, and delicate chin, whereas older patients have slightly coarse features, with full lips, a wide smile, and a full nasal tip.

The extent of medical and developmental problems in patients with Williams–Beuren syndrome is highly variable. Common features affecting each organ system are listed in Table 1. This review emphasizes findings in the cardiovascular, endocrine, and nervous systems that most affect morbidity and mortality.

CARDIOVASCULAR ABNORMALITIES

Stenosis of medium and large arteries owing to thickening of the vascular media from smooth-muscle overgrowth constitutes the prototypical cardiovascular abnormality of Williams–Beuren syndrome. Stenosis is most commonly located above the aortic valve at the sinotubular junction (e.g., supralvalvular aortic stenosis) (Fig. 2E and 2F).

Supralvalvular aortic stenosis, the severity of which ranges from trivial to severe, is found in approximately 70% of patients and is rare except in Williams–Beuren syndrome¹⁶ and the related familial supralvalvular aortic stenosis syndrome. Arterial narrowing may be isolated or may occur simultaneously in numerous locations, including the aortic arch, the descending aorta (Fig. 2G and 2H), and the pulmonary, coronary, renal (Fig. 2G), mesenteric (Fig. 2H), and intracranial arteries. Noninvasive imaging such as echocardiography^{17–21} reveals, in most patients, lesions ranging from discrete (e.g., “hourglass”) narrowing to multiple stenotic areas or, occasionally, even diffuse hypoplasia. An increased carotid artery intima–media thickness,²² consistent with a generalized elastin arteriopathy, is present in all cases. Rarely, patients are found to have “middle aortic syndrome,” in which the thoracic aorta and abdominal aorta and

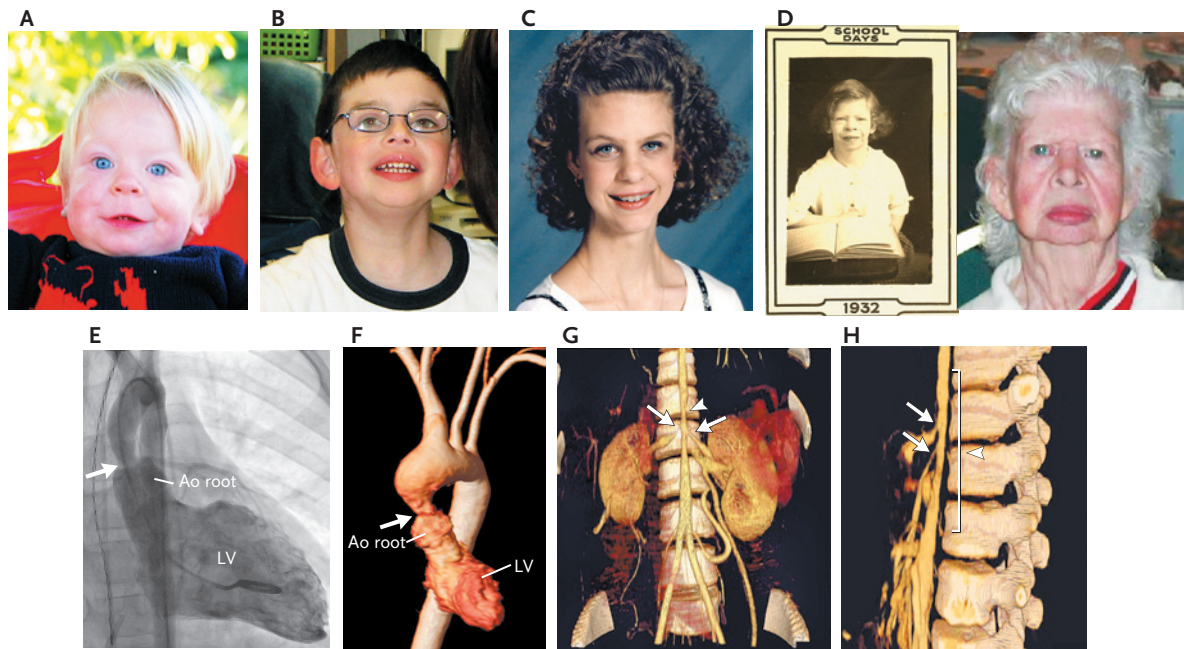


Figure 2. Patients with Williams-Beuren Syndrome.

Four unrelated patients with Williams-Beuren syndrome are shown in Panels A through D. The young child (Panel A) has a flat nose bridge, upturned tip of nose, long philtrum, mild periorbital puffiness, full cheeks, and a delicate chin. The school-age child (Panel B) has full lips, a wide mouth, and mildly increased interdental spacing. The young adult (Panel C) has a prominent nose and nasal tip, a wide mouth, and a full lower lip. Panel D shows a patient at 12 years of age (left) and at 83 years of age (right). Vascular stenoses in unrelated patients are shown in Panels E through H. Left ventriculography in a 5-year-old boy with Williams-Beuren syndrome shows a severe discrete (so-called hourglass) supravulvar aortic stenosis (Panel E, arrow). The aortic (Ao) root is dilated, and the proximal ascending aorta is mildly hypoplastic. Volume-rendered gadolinium-enhanced three-dimensional magnetic resonance angiography in a 44-year-old woman with Williams-Beuren syndrome shows moderate discrete supravulvar aortic stenosis (Panel F, arrow) and post-stenotic dilatation. Panels G and H show the anteroposterior and lateral views, respectively, from computed tomographic angiography in a 13-year-old boy with hypertension and an abdominal bruit. There is marked tapering of the descending aorta (Panel G, arrowhead) and stenosis at the origin of the renal arteries (arrows); an aberrant course of the renal arteries is also visible. Tapering of the descending aorta (Panel H, bracket and arrowhead) with stenosis of celiac and superior mesenteric arteries (arrows) can be seen. LV denotes left ventricle.

its branches are narrowed.^{23,24} Intracardiac lesions such as ventricular or atrial septal defects are uncommon, whereas myxomatous degeneration of aortic or mitral-valve leaflets, or both, occur in up to 20% of patients.^{17,25} Left-sided stenoses may remain stable, but obstruction can progress, especially during the first 5 years of life. However, obstruction of right ventricular outflow, particularly peripheral pulmonary stenoses, often resolves spontaneously.^{21,26} Stenosis or occlusion of coronary ostia can occur in the absence of supravulvar aortic stenosis.²⁷

Hypertension, occasionally beginning in childhood, ultimately develops in approximately 50% of patients.^{28,29} The basis for hypertension is often not identified; surgically repairable renovascular lesions are infrequent. Animal models suggest

that the higher blood pressures in patients with Williams-Beuren syndrome than in controls may reflect a physiological adaptation to abnormal vasculature.³⁰

Cardiovascular complications are the major cause of death in patients with Williams-Beuren syndrome. A formal assessment of the life expectancy associated with Williams-Beuren syndrome is lacking. One study of approximately 300 patients, 1 to 55 years of age, with Williams-Beuren syndrome showed a cardiovascular-associated mortality 25 to 100 times that among the controls.³¹ The administration of general anesthesia for cardiac catheterization or for cardiac surgery in patients with Williams-Beuren syndrome who have biventricular outflow obstruction, biventricular hypertrophy, or stenosis or occlusion of coronary

Table 1. Common Features of Williams–Beuren Syndrome, According to Organ System.*

Feature†	Comments‡
Auditory and ear, nose, and throat	
Hyperacusis	Noise sensitivity can negatively affect quality of life
Mild-to-moderate high-tone sensorineural hearing loss	Clinically detected in adolescents and adults
Recurrent otitis media	
Cardiovascular	
Vascular stenosis (e.g., SVAS, PPS)	Change in stenosis most likely to occur during childhood; surgery often indicated for greater-than-moderate SVAS
Hypertension	Renovascular cause occasionally found
Valve abnormality (e.g., MVP)	
Intracardiac lesion (e.g., VSD)	
Stroke	Very rare; can be secondary to intracranial stenosis
Sudden death	Very rare; risk factors are use of anesthesia, biventricular outflow obstruction, biventricular hypertrophy, coronary-artery obstruction
Development and cognition	
Global cognitive impairment (mean IQ, about 55)	IQ ranges from 40 to 100; a few patients have IQs within the normal range
Characteristic pattern of cognitive strengths and weaknesses (known as the Williams–Beuren syndrome cognitive profile)	Strengths are in selected language skills and weaknesses in visuospatial skills
Dental	
Small or unusually shaped primary teeth	
Malocclusions	
Hypodontia	
Endocrine	
Early onset of puberty	Menarche occurs about 2 years early
Glucose intolerance or diabetes mellitus	Reported in 75% of adults
Osteopenia or osteoporosis	Vitamin D or calcium supplementation should be used with caution
Hypothyroidism (subclinical)	Can be associated with mild thyroid hypoplasia; drug therapy required in minority
Hypercalcemia	Documented in a minority of patients; not restricted to infancy
Gastrointestinal and weight-related	
Colic, difficulty feeding, textured-food intolerance	
Abnormal weight gain	Many infants gain weight poorly; as adults, two thirds have a body-mass index >25§
Constipation	
Gastroesophageal reflux	
Abdominal pain of unclear cause	
Diverticular disease	Possibly occurs in up to one third of patients; diverticulitis can occur in young adults
Rectal prolapse	
Celiac disease	

Table 1. (Continued.)

Feature†	Comments‡
Genitourinary	
Delayed toilet training	
Voiding frequency, urgency, enuresis	
Structural renal anomalies	
Bladder diverticula	
Recurrent urinary tract infections	
Nephrocalcinosis	
Miscellaneous	
Short stature	Common but not obligatory; cause is probably multifactorial
Sleep dysregulation, possibly including restless legs syndrome	Prevalence is currently unknown
Musculoskeletal	
Joint laxity	
Joint contractures	Worsening lower-extremity contractures with increasing age
Lordosis	
Scoliosis	
Neurologic	
Hypotonia	
Hyperreflexia	More prevalent in adolescents and adults than in younger patients, especially in lower extremities
Cerebellar findings	Poor balance and coordination
Type I Chiari malformation	
Ophthalmologic	
Strabismus	
Altered visual acuity	
Reduced stereopsis	
Narrowing of lacrimal duct	
Personality, behavior, and emotional well-being	
Friendly personality	Endearing, friendly personality that can confer vulnerability to inappropriate advances
Impulsivity and short attention span (ADHD)	Lifelong ADHD, declining hyperactivity after childhood
Anxiety and phobias, obsessive–compulsive traits	Anxiety and other traits develop over time and are present in a majority of adolescents and adults
Dysthymia	
Skin and integument	
Soft skin with mild premature aging	
Premature graying of hair	Can start in young adulthood
Inguinal (and other) hernias	

* ADHD denotes attention deficit–hyperactivity disorder, MVP mitral-valve prolapse, PPS peripheral pulmonary stenosis, SVAS supravulvular aortic stenosis, and VSD ventricular septal defect.

† Common features are listed in descending order of prevalence.

‡ Comments are listed for the features for which the trajectory is particularly distinctive in Williams–Beuren syndrome.

§ The body-mass index is the weight in kilograms divided by the square of the height in meters.

ostia has been reported to increase the relative risk of adverse outcomes.²⁷

ENDOCRINE ABNORMALITIES

Among endocrine abnormalities associated with Williams–Beuren syndrome, hypercalcemia has received the most attention for historical reasons, even though it is often documented less frequently than other problems such as diabetes mellitus or subclinical hypothyroidism.

Calcium Abnormalities

It has been reported that 5%^{32,33} to 50%^{34,35} of patients with Williams–Beuren syndrome have one or more episodes of hypercalcemia; this factor-of-10 variation is most likely due to differing study designs and methods. Hypercalcemia is generally mild (with calcium levels up to 11.5 mg per deciliter [2.9 mmol per liter]), though it can be moderate or severe, particularly during infancy.^{36,37} An episode of hypercalcemia can be asymptomatic or associated with nonspecific symptoms (e.g., colic or irritability, hypotonia, diminished appetite, and constipation) that commonly occur even in patients with Williams–Beuren syndrome who have eucalcemia. Hypercalciuria generally accompanies hypercalcemia, but isolated hypercalciuria, especially after infancy, can also occur. Nephrocalcinosis is relatively rare, found in less than 5 to 10% of patients undergoing renal ultrasonography.^{32,38–40}

Various mechanisms have been suggested to cause hypercalcemia, but none have been confirmed. The proposed mechanisms include vitamin D sensitivity,⁴¹ increased 1,25-dihydroxyvitamin D levels,⁴² and defective calcitonin synthesis or release.⁴³

Nine of 20 adult subjects in one study had decreased bone mineral density at multiple sites on dual-energy x-ray absorptiometry; all had normal blood calcium levels, save 1: a 41-year-old man whose calcium level was 10.6 mg per deciliter (2.7 mmol per liter) (normal range, 8.8 to 10.2 [2.2 to 2.6]).⁴⁴ Since decreased bone density is more prevalent among adults with developmental disabilities⁴⁵ than among adults in the general population, this finding may be nonspecific.

Diabetes Mellitus

The prevalence of impaired glucose tolerance is unusually high among patients with Williams–Beuren syndrome — even higher than the increased prevalence reported among the Pima Indians.⁴⁶

In one study of 20 adults with Williams–Beuren syndrome, oral glucose-tolerance testing showed that 7 had silent diabetes, 9 had impaired glucose tolerance, and only 2 had normal results; the remaining 2 patients had previously diagnosed diabetes that contraindicated oral glucose-tolerance testing.⁴⁴ Obesity was an additional risk factor; glucose tolerance was abnormal in 10 of the 12 patients with Williams–Beuren syndrome who had a body-mass index (BMI; the weight in kilograms divided by the square of the height in meters) greater than 25, as compared with only 2 of 12 healthy controls matched with regard to age, sex, and BMI. However, among subjects with a BMI below 20, three of six with Williams–Beuren syndrome, as compared with none of six matched controls, had impaired glucose tolerance. Overt diabetes has been reported in several adults with Williams–Beuren syndrome.¹⁸

Thyroid Abnormalities

Subclinical hypothyroidism, diagnosed in 15 to 30% of patients screened,^{47,48} is often accompanied by mild thyroid hypoplasia on ultrasonography. Overt hypothyroidism appears to be infrequent. Antithyroid antibodies have not been reported in children with Williams–Beuren syndrome.

Other Endocrine Issues

Most children with Williams–Beuren syndrome have decreased annual height velocity and an early, attenuated adolescent growth spurt; this growth pattern contributes to diminished adult stature. Menarche occurs, on average, 2 years earlier than in controls.^{18,44,49,50} No specific endocrine disturbances responsible for early menarche have been reported. Data from patients with Williams–Beuren syndrome have been used to construct growth curves that can be used to monitor linear growth.^{18,49,51}

NEURODEVELOPMENTAL ABNORMALITIES

Development and Cognition

Young children with Williams–Beuren syndrome have delays in acquisition of early motor skills and in achievement of language milestones. Standardized testing in older children and adults demonstrates a full-scale IQ averaging 50 to 60, indicative of mild-to-moderate intellectual disability.^{52,53} Across the entire spectrum of children and adults with Williams–Beuren syndrome, IQ ranges from 40 to 100.⁵³ However, cognition in Williams–Beuren

syndrome is more complex than indicated by IQ alone.

Many — but not all — studies report a higher average verbal IQ than performance IQ in patients with Williams–Beuren syndrome. The Williams–Beuren syndrome cognitive profile, describing a common pattern of cognitive peaks and valleys, encompasses relative strengths in auditory rote memory (e.g., digit recall) and selected aspects of language, combined with dramatic weaknesses in visuospatial and visuomotor skills (the ability to spatially relate objects, such as assembling a jigsaw puzzle).⁵⁴ Patients with Williams–Beuren syndrome also have relative strengths in facial recognition and discrimination and in social and interpersonal skills.⁵³

Few studies have examined the IQ of patients with Williams–Beuren syndrome over time, but limited data suggest it remains stable.^{55,56} Nonetheless, several older adults have exhibited declining performance on selected memory tasks, and a few patients with premature senile dementia have been reported.^{44,57}

Personality and Behavioral and Emotional Well-Being

The friendly, social (perhaps overly so), “cocktail party” personality of patients with Williams–Beuren syndrome patients is well described, and most patients are, indeed, highly social and empathic. Many also have coexisting behavioral difficulties, even psychopathology. Notably, patients have excessive worry and fears; parents and caregivers report that more than 80% of adults with Williams–Beuren syndrome have anxiety, preoccupations or obsessions, distractibility, and irritability.⁵⁸ Expert assessments reveal that 50 to 90% of adolescents and adults meet the diagnostic criteria of the *Diagnostic and Statistical Manual of Mental Disorders, Fourth Edition*, for anxiety disorder, phobic disorder, attention deficit–hyperactivity disorder, or a combination thereof. In spite of the friendly personality of patients, many are socially isolated.^{44,59,60} Almost all have prominent anticipatory anxiety (e.g., about upcoming events) but an absence of social anxiety (e.g., about meeting strangers). These difficulties have a great effect on the quality of life of most people with Williams–Beuren syndrome.

Enjoyment of music is nearly universal in patients with Williams–Beuren syndrome. However, initial suggestions that a high proportion are musically gifted, with perfect pitch, have not been

substantiated.⁶¹ In a seeming paradox, sensitivity to certain noises, particularly thunderstorms or fireworks, develops in up to 90% of cases.⁶²

Neurologic Examination and Brain Imaging

Standard magnetic resonance imaging (MRI) of the brain reveals an overall 10 to 15% reduction in cerebral volume, with preserved cerebellar volume.⁶³ The most commonly detected medically important structural abnormality is type I Chiari malformation⁶⁴; its prevalence is unknown, because MRI imaging is not routinely performed, but as many as 10% of patients may be affected.⁶⁵ Hyperreflexia, clonus, extrapyramidal signs, and cerebellar signs occur in 40 to 70% of subjects across a wide range of ages.^{66,67}

Studies involving functional MRI scanning are ongoing to delineate the neurologic underpinnings of distinctive manifestations of Williams–Beuren syndrome, such as deficient visuospatial skills and increased anxiety.⁵² In one study, patients performing object-matching tasks showed normal activation of the visual cortex’s ventral-stream circuit (used in addressing “what” questions), but while performing tasks requiring spatial localization, the same patients showed hypoactivation and hypoplasia of the relevant intraparietal sulcus circuit (used for “where” questions).⁶⁸ Patients also show diminished amygdala activation when viewing threatening or angry faces but increased activation in response to threatening stimuli of a nonsocial nature, suggesting that impaired limbic circuitry may underlie the unique anxiety profile of Williams–Beuren syndrome.⁶⁹

PROBLEMS ACROSS THE LIFE SPAN

Patients with Williams–Beuren syndrome need lifelong medical attention. Some conditions common in infants — such as colic, sleep dysregulation, recurrent ear infections, and strabismus — occur even more frequently in infants with Williams–Beuren syndrome, prompting an average of almost 10 extra visits to the pediatrician during the first year of life.¹⁸ Certain findings that are highly particular to Williams–Beuren syndrome, such as hypercalcemia or progression of vascular stenosis (e.g., supravalvular aortic stenosis), are most likely to be noted during, but are not restricted to, the first 3 to 5 years of life. Premature graying of the hair, diverticulosis, diabetes mellitus, and sensorineural hearing loss commonly develop during adolescence or young

adulthood; their occurrence relatively early in life, in combination with instances of declining memory skills or dementia, raises the possibility that Williams–Beuren syndrome is a disorder of mild accelerated aging. Most adults with Williams–Beuren syndrome require ongoing supervision at both their home and workplace. Only a few live independently or have full-time employment in competitive work environments.

GENOMIC AND GENETIC BASIS OF WILLIAMS–BEUREN SYNDROME

The chromosome 7 microdeletion underlying Williams–Beuren syndrome occurs because of the unique genetic architecture in this region. Specifically, the deleted region, referred to as the Williams–Beuren syndrome chromosome region, is flanked by highly homologous clusters of genes and pseudogenes organized into low-copy-repeat blocks known as duplicons (Fig. 3A). The high degree of sequence homology among these flanking duplicons, as well as their proximity to each other, predispose the Williams–Beuren syndrome chromosome region on each chromosome 7 to misalign during meiosis; if unequal crossing over ensues, the region can be deleted (Fig. 3C). The deletion arises on either the maternally or the paternally inherited chromosome 7 and is sporadic (e.g., *de novo*) in virtually all cases. Thus, healthy parents do not carry the deletion, which occurs spontaneously during gamete formation, so the probability of their having a second child with Williams–Beuren syndrome child is far less than 1%. Most adults with Williams–Beuren syndrome choose not to reproduce, but those who do have a 50:50 chance that each offspring will inherit the syndrome.^{9,10}

In more than 98% of patients who receive a clinical diagnosis of Williams–Beuren syndrome, the breakpoints in the Williams–Beuren syndrome chromosome region occur within the duplicons (Fig. 3A).^{70,71} Most breaks occur in the medial and centromeric duplicons, specifically the B blocks, and lead to the deletion of approximately 1.5 million DNA base pairs encoding 26 to 28 genes; less often, a slightly larger deletion of 1.8 million base pairs encoding all 28 genes occurs.⁷¹ No phenotypic differences, apart from the risk of hypertension, have been noted between patients who have deletions of either size.

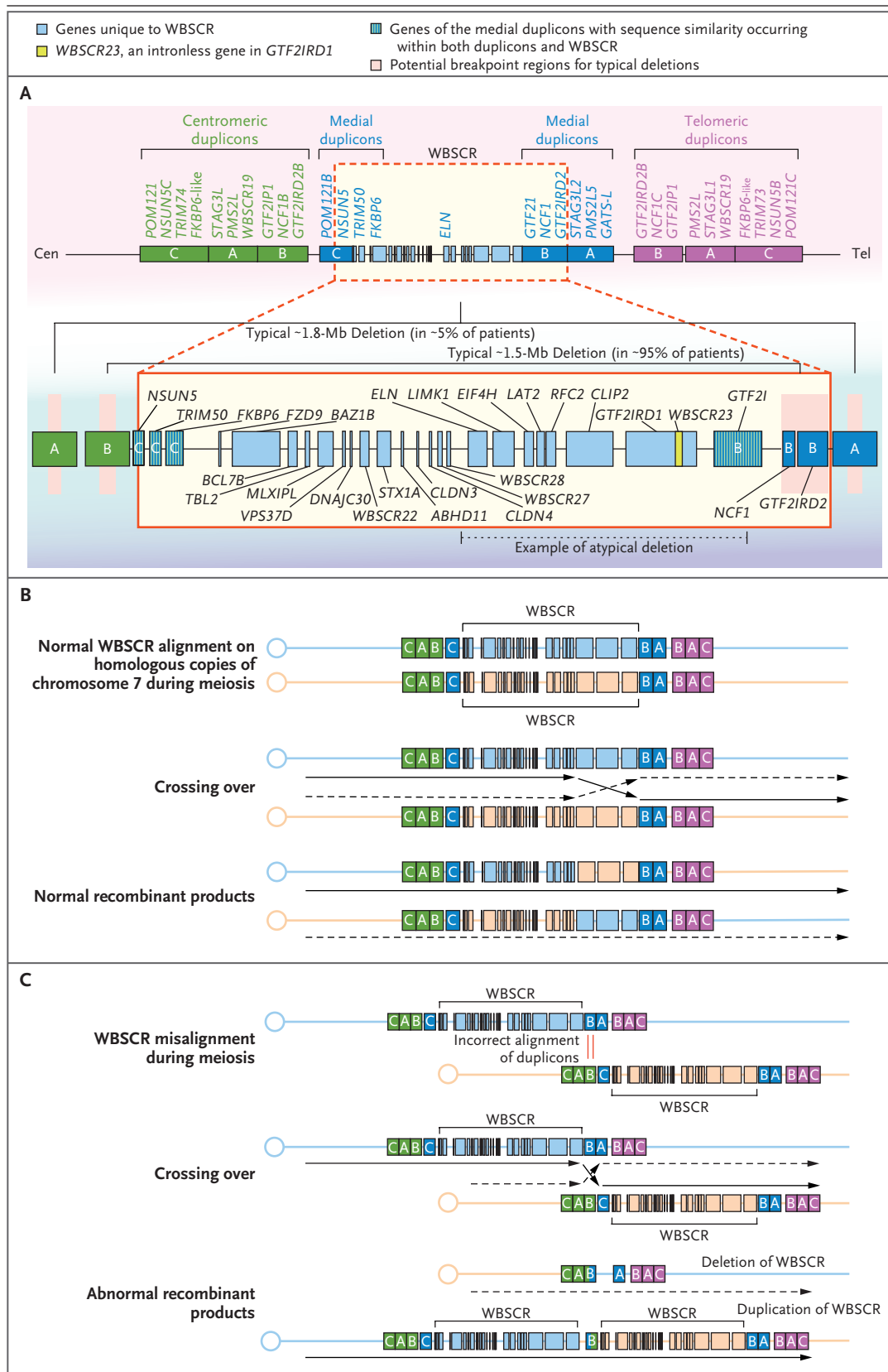
About 2% of patients have atypical deletions

Figure 3 (facing page). The Williams–Beuren Syndrome Chromosome Region (WBSCR) on Chromosome 7.

Panel A (top) shows the WBSCR located between flanking blocks of low-copy DNA repeats, known as duplicons. Panel A (middle) also shows the most common WBSCR deletions, approximately 1.5 Mb and 1.8 Mb in size; breakpoint regions responsible for these deletions occur in the centromeric and medial duplicon B blocks and the A blocks, respectively. An enlargement of the WBSCR, depicting the genes unique to this interval, is shown in Panel A (bottom, with the width of the rectangle roughly corresponding to gene size). Panel A (bottom) also shows an example of WBSCR deletions of atypical size. Cen denotes centromere, and Tel telomere. Panel B shows normal pairing of the two copies of the WBSCR during meiosis, caused by alignment of the centromeric, medial, and telomeric duplicons on the chromosome 7 homologues. Panel C shows abnormal pairing of the two copies of the WBSCR during meiosis, caused by misalignment of the centromeric and medial duplicons due to their partial homology. Crossing over can result in abnormal recombinant products, either deletion of the WBSCR (causing Williams–Beuren syndrome) or duplication of WBSCR. The open circles in Panels B and C denote the centromere. Panels A, B, and C are schematized, not drawn to scale.

(Fig. 3A).⁷² Those with a small atypical deletion involving the telomeric portion of the Williams–Beuren syndrome chromosome region have common characteristics of the syndrome whereas, conversely, those whose atypical deletion spares this portion of the chromosome region have milder features of Williams–Beuren syndrome.^{73,74} Taken together, these findings indicate that deletion of genes near the telomeric end only is sufficient to lead to the typical neurodevelopmental profile of Williams–Beuren syndrome. Several patients with a more complex phenotype, including severe developmental delays and seizures, have a larger-than-typical deletion.⁷⁵

The duplicons flanking the Williams–Beuren syndrome chromosome region also predispose the intervening region to genetic changes such as duplication (Fig. 3C) or inversion. Patients with duplication of the Williams–Beuren syndrome chromosome region, who therefore carry three copies of all the genes therein, do not physically or cognitively resemble patients with Williams–Beuren syndrome; their cognitive profile includes impairment of expressive language skills, developmental delays, and, in some cases, autistic-like features.^{76,77} Inversion (e.g., flipping) of the entire Williams–Beuren syndrome chromosome region is considered a benign polymorphism, since carriers are



phenotypically normal.⁷⁸ However, inversion carriers are more likely to produce a gamete harboring the deleted Williams–Beuren syndrome chromosome region, because of an increase in chromosome 7 mispairing events during meiosis.^{79,80} The presence of a small deletion or duplication within a low-copy-repeat block is another risk factor for meiotic mispairing.⁸¹

GENES CONTRIBUTING TO THE WILLIAMS–BEUREN SYNDROME PHENOTYPE

Although the loss of an *ELN* allele produces the cardiovascular pathology of Williams–Beuren syndrome, the phenotypic consequences of losing other alleles within the Williams–Beuren syndrome chromosome region are much less clear. The effects of hemizygoty (in which only one member of a gene pair, rather than the usual two, is present) have been inferred from the study of patients with atypical deletions and mouse models that either overexpress or underexpress genes of interest. The Williams–Beuren syndrome chromosome region in humans and its corresponding region in mice are similar, containing nearly the same genes in the same order. Single-gene–knockout mice and a new multigene–knockout mouse model, in which all genes in the Williams–Beuren syndrome chromosome region are simultaneously deleted, may further define each gene’s role and whether selected phenotypes require combinatorial loss of several genes.⁸² Genes currently implicated in the phenotype of Williams–Beuren syndrome are listed in Table 2 (see also a complete listing of genes in the Williams–Beuren syndrome chromosome region in the Supplementary Appendix, available with the full text of this article at NEJM.org, and in a recent review by Schubert⁸³).

The presence of only one copy, rather than two copies, of each gene in the Williams–Beuren syndrome chromosome region should reduce the expression of encoded proteins by half. Although empirical data confirm that this occurs with most of the genes, there are tissue-specific exceptions, such as *GTF2IRD1* (the gene encoding general transcription factor II-I repeat domain-containing protein 1).⁸⁴ In addition, several nondeleted genes that flank the Williams–Beuren syndrome chromosome region unexpectedly display diminished expression, possibly due to the position effect.

Despite genetic advances, the considerable phenotypic variability observed among patients with Williams–Beuren syndrome remains unexplained.

Initial speculation that variation in the size of the deletion accounted for this variability was disproven. Probable explanations include polymorphisms in the nondeleted copies of genes in the Williams–Beuren syndrome chromosome region that affect protein function or expression level, variable effects of the deletion on the expression of neighboring genes, or the effects of modifier genes, including epigenetic alterations, elsewhere in the genome. Currently, there is no genetic test that predicts the severity of the Williams–Beuren syndrome phenotype in a given patient.

MANAGEMENT

The primary care physician remains the principal provider and care coordinator for patients with Williams–Beuren syndrome. Current management guidelines are based on expert opinion rather than prospectively collected data. Treatment involves a combination of medical monitoring, anticipatory guidance, direct therapies, pharmacotherapy, surgery, and adaptive changes (e.g., using a microwave rather than a conventional range for cooking and wearing shoes with hook-and-loop closures rather than shoelaces). None of the available treatments are curative. Examples of treatments with specific modifications for Williams–Beuren syndrome are highlighted below; a more global synthesis of management guidelines is presented in the Supplementary Appendix.^{15,44,85–89}

Surgery is the preferred approach for repair of discrete moderate-to-severe aortic stenoses. Less invasive procedures such as balloon angioplasty and stent insertion have been successful but carry a higher risk of rupture, aneurysm, or restenosis, as might be expected given the characteristic overgrowth of vascular smooth muscle.^{90–92} The pulmonary arteries have less smooth muscle and are candidates for angioplasty, but pulmonary-artery lesions in patients with Williams–Beuren syndrome, particularly in the absence of supravalvular aortic stenosis, can often be monitored, since many resolve spontaneously. To date, there have been no systematic studies identifying optimal medication to treat hypertension in Williams–Beuren syndrome, so treatment has been individualized.

Williams–Beuren syndrome can be viewed as a polyendocrine disorder with potential involvement of all endocrine organs. Subclinical hypothyroidism is far more common than “true”

Table 2. Human Genes That Are Hemizygous in Patients with Williams–Beuren Syndrome with a Putative Effect on Phenotype.*

Hemizygous Gene and Putative Effect	Likelihood of Effect	Data Sources†
FZD9		
Osteopenia	Possible	Mouse models
BAZ1B		
Hypercalcemia, intracardiac malformations	Possible	Mouse models
STX1A		
Impaired glucose tolerance	Possible	Mouse models, other human populations
ELN		
Arteriopathy with vascular stenoses, hypertension, vascular smooth-muscle-cell overgrowth	Definite	Mouse models, other human populations, and atypical deletions
Soft skin with premature aging, hoarse voice, inguinal hernias	Probable	Other human populations
Facial dysmorphism	Possible	Other human populations
LIMK1		
Impaired visuospatial abilities	Possible	Mouse models, atypical deletions
CLIP2		
Impaired visuospatial and motor abilities	Possible	Mouse models, atypical deletions
GTF2I family, including GTF2IRD1		
Craniofacial abnormalities, dental abnormalities, growth retardation, behavioral abnormalities, intellectual disability, WBS cognitive profile, decreased retinal thickness, impaired visual responses	Possible	Mouse models, atypical deletions
NCF1		
Reduced risk of hypertension	Possible	Fine mapping of WBSCR

* In patients with Williams–Beuren syndrome (WBS), the unique sequence genes that map to the WBS chromosome region (WBSCR) are hemizygous, having one copy present rather than the usual two. Listed here are only the subgroup of WBSCR genes currently implicated in specific aspects of the WBS phenotype: the frizzled 9 gene (*FZD9*); bromodomain adjacent to a zinc-finger domain protein 1B gene (*BAZ1B*, which is also called Williams syndrome transcription factor gene [*WSTF*]); syntaxin 1A gene (*STX1A*); elastin gene (*ELN*); LIM domain kinase 1 (*LIMK1*); CAP-GLY domain containing linker protein 2 gene (*CLIP2*); the general transcription factor II-I gene (*GTF2I*) family, including *GTF2I* repeat domain-containing protein 1 gene (*GTF2IRD1*); and neutrophil cytosolic factor 1 gene (*NCF1*).

† The data source “other human populations” refers to inferences drawn from patients with familial supravalvular aortic stenosis syndrome or populations not affected by Williams–Beuren syndrome. “Atypical deletions” refer to genotype–phenotype inferences drawn from patients with nonstandard (i.e., atypical) deletions involving the WBSCR. See the Supplementary Appendix for additional details.

hypothyroidism, requiring monitoring but not necessarily treatment with thyroid hormone. Some patients receiving thyroid hormone may benefit from a brief, carefully supervised period in which no treatment is given, to determine whether ongoing supplementation is needed. Given the high prevalence of glucose intolerance, adults with Williams–Beuren syndrome should undergo routine screening; though glucose homeostasis is achievable through weight loss and increased physical activity, the addition of an oral hypoglycemic agent or insulin under careful medical supervision

may be required. Early puberty, a common occurrence in patients with Williams–Beuren syndrome, does not require treatment per se; however, given the challenges faced by a menstruating 8- or 9-year-old girl with Williams–Beuren syndrome, some families opt to reversibly delay menarche with the use of a gonadotropin-releasing hormone agonist such as leuprolide.⁹³ Finally, symptoms of hypercalcemia may be absent or nonspecific, necessitating periodic but lifelong screening of calcium levels. There are several treatment options for hypercalcemia, ranging from dietary calcium restric-

tion (accomplished in infants by means of specialized low-calcium formulas or elimination of hard water for formula preparation) to bisphosphonate therapy.³⁷ Whether or not osteopenia in patients with Williams–Beuren syndrome represents a specific defect in calcium metabolism, it can be particularly challenging to treat, in that calcium and vitamin D supplementation may promote hypercalcemia; administration of a bisphosphonate is currently the treatment of choice for markedly decreased bone density in these patients.⁴⁴

The presence or absence of emotional and psychiatric issues largely determines the quality of life for adults with Williams–Beuren syndrome. When present, these can be especially challenging to manage. Approximately half of adolescents and adults are being treated or have been treated with an anxiolytic agent. Typically, a selective serotonin-reuptake inhibitor is the initial drug of choice, even though reports of efficacy are anecdotal. Patients with Williams–Beuren syndrome appear particularly sensitive to the disinhibiting effects of these drugs, so treatment should be judicious. Other agents, including antipsychotic drugs, are occasionally prescribed, but to date there are no systematic data on their use in patients with Williams–Beuren syndrome. Patients with relatively strong verbal skills may benefit from counseling, including the practice of relaxation techniques and rehearsal of strategies to use in potentially anxiety-provoking situations. Finding appropriately experienced therapists willing to evaluate and treat patients with Williams–Beuren syndrome remains an enormous obstacle.

For individuals with special needs or intellectual disabilities, transitioning from pediatric to adult-oriented medical providers can be problematic, potentially resulting in fragmented, suboptimal care. The core impediments to improving care, as well as potential solutions, are discussed elsewhere.⁹⁴ The Internet is an increasingly valuable tool, not only for identifying resources regarding

this transition but also for promoting communication and family support among people with rare disorders and for promoting clinical research and treatment trials (see the Supplementary Appendix).

FUTURE DIRECTIONS

Williams–Beuren syndrome is a complex medical and neurodevelopmental disorder with a characteristic constellation of problems but also considerable phenotypic variability. The complexity arises from the deletion of more than two dozen genes in the Williams–Beuren syndrome chromosome region, whereas the variability may be due to their interaction with products from other genes outside this region. Microdeletion syndromes offer powerful opportunities for studying genotype–phenotype correlations. In the case of Williams–Beuren syndrome, such study has been particularly successful, linking the deletion of an elastin allele to vascular stenosis. Less progress has been made in drawing connections between aspects of the neurodevelopmental profile and specific genes within the Williams–Beuren syndrome chromosome region. Nevertheless, the Williams–Beuren syndrome may ultimately provide important insights into causation and potential treatments of overlapping disorders occurring sporadically in the general population.

Supported in part by a grant from the Williams Syndrome Association for development of the Williams Syndrome Patient and Clinical Research Registry (see the Supplementary Appendix). No other potential conflict of interest relevant to this article was reported.

I thank Jessica Waxler, M.S., and Lucy Osborne, Ph.D., for invaluable comments and advice on the manuscript and for particular assistance with a previous version of Figure 3 and Table 1 in the Supplementary Appendix, respectively; Dr. Sibel Kantarci of Beth Israel Deaconess Medical Center, Boston, for kindly providing the image in Figure 1A; Drs. Yiping Shen, Bai-Lin Wu, and David Miller of Children's Hospital, Boston, for kindly providing the image in Figure 1B; Dr. Tal Geva of Children's Hospital, Boston, for providing the images of supravalvular aortic stenosis in Figure 2E and 2F; and the Williams Syndrome Association for assistance in obtaining photographs for publication and the families who kindly provided them.

REFERENCES

1. Strømme P, Bjørnstad PG, Ramstad K. Prevalence estimation of Williams syndrome. *J Child Neurol* 2002;17:269-71.
2. Schlesinger BE, Butler NR, Black JA. Severe type of infantile hypercalcaemia. *Br Med J* 1956;1:127-34.
3. Bongiovanni AM, Eberlein WR, Jones IT. Idiopathic hypercalcemia of infancy, with failure to thrive: report of three cases, with a consideration of the possible etiology. *N Engl J Med* 1957;257:951-8.
4. Williams JC, Barratt-Boyes BG, Lowe JB. Supravalvular aortic stenosis. *Circulation* 1961;24:1311-8.
5. Beuren AJ, Apitz J, Harmjanz D. Supravalvular aortic stenosis in association with mental retardation and a certain facial appearance. *Circulation* 1962;26:1235-40.
6. Garcia RE, Friedman WF, Kaback MM, Rowe RD. Idiopathic hypercalcemia and supravalvular aortic stenosis: documentation of a new syndrome. *N Engl J Med* 1964;271:117-20.
7. Friedman WF, Roberts WC. Vitamin

- D and the supravalvular aortic stenosis syndrome: the transplacental effects of vitamin D on the aorta of the rabbit. *Circulation* 1966;34:77-86.
8. Friedman WF, Mills LF. The relationship between vitamin D and the craniofacial and dental anomalies of the supravalvular aortic stenosis syndrome. *Pediatrics* 1969;43:12-8.
 9. Sadler LS, Robinson LK, Verdaasdonk KR, Gingell R. The Williams syndrome: evidence for possible autosomal dominant inheritance. *Am J Med Genet* 1993;47:468-70.
 10. Morris CA, Thomas IT, Greenberg F. Williams syndrome: autosomal dominant inheritance. *Am J Med Genet* 1993;47:478-81.
 11. Johnson LW, Fishman RA, Schneider B, Parker FB Jr, Husson G, Webb WR. Familial supravalvular aortic stenosis: report of a large family and review of the literature. *Chest* 1976;70:494-500.
 12. Curran ME, Atkinson DL, Ewart AK, Morris CA, Leppert ME, Keating MT. The elastin gene is disrupted by a translocation associated with supravalvular aortic stenosis. *Cell* 1993;73:159-68.
 13. Ewart AK, Morris CA, Atkinson D, et al. Hemizygoty at the elastin locus in a developmental disorder, Williams syndrome. *Nat Genet* 1993;5:11-6.
 14. Preus M. The Williams syndrome: objective definition and diagnosis. *Clin Genet* 1984;25:422-8.
 15. American Academy of Pediatrics. Health care supervision for children with Williams syndrome. *Pediatrics* 2001;107:1192-204. [Erratum, *Pediatrics* 2002;109:329.]
 16. Pober BR, Johnson M, Urban Z. Mechanisms and treatment of cardiovascular disease in Williams-Beuren syndrome. *J Clin Invest* 2008;118:1606-15.
 17. Eronen M, Peippo M, Hiipala A, et al. Cardiovascular manifestations in 75 patients with Williams syndrome. *J Med Genet* 2002;39:554-8.
 18. Morris CA, Demsey SA, Leonard CO, Dilts C, Blackburn BL. Natural history of Williams syndrome: physical characteristics. *J Pediatr* 1988;113:318-26.
 19. Hallidie-Smith KA, Karas S. Cardiac anomalies in Williams-Beuren syndrome. *Arch Dis Child* 1988;63:809-13.
 20. Zalzstein E, Moes CA, Musewe NN, Freedom RM. Spectrum of cardiovascular anomalies in Williams-Beuren syndrome. *Pediatr Cardiol* 1991;12:219-23.
 21. Wang CC, Hwu WL, Wu ET, Lu F, Wang JK, Wu MH. Outcome of pulmonary and aortic stenosis in Williams-Beuren syndrome in an Asian cohort. *Acta Paediatr* 2007;96:906-9.
 22. Sadler LS, Gingell R, Martin DJ. Carotid ultrasound examination in Williams syndrome. *J Pediatr* 1998;132:354-6.
 23. Radford DJ, Pohlnar PG. The middle aortic syndrome: an important feature of Williams' syndrome. *Cardiol Young* 2000;10:597-602.
 24. Rose C, Wessel A, Pankau R, Partsch CJ, Bürsch J. Anomalies of the abdominal aorta in Williams-Beuren syndrome — another cause of arterial hypertension. *Eur J Pediatr* 2001;160:655-8.
 25. Scheiber D, Fekete G, Urban Z, et al. Echocardiographic findings in patients with Williams-Beuren syndrome. *Wien Klin Wochenschr* 2006;118:538-42.
 26. Wessel A, Pankau R, Kececioğlu D, Ruschewski W, Bursch JH. Three decades of follow-up of aortic and pulmonary vascular lesions in the Williams-Beuren syndrome. *Am J Med Genet* 1994;52:297-301.
 27. Burch TM, McGowan FX Jr, Kussman BD, Powell AJ, DiNardo JA. Congenital supravalvular aortic stenosis and sudden death associated with anesthesia: what's the mystery? *Anesth Analg* 2008;107:1848-54.
 28. Broder K, Reinhardt E, Ahern J, Lifton R, Tamborlane W, Pober B. Elevated ambulatory blood pressure in 20 subjects with Williams syndrome. *Am J Med Genet* 1999;83:356-60.
 29. Wessel A, Motz R, Pankau R, Bürsch JH. Arterielle Hypertension und Blutdruckprofil bei Patienten mit Williams-Beuren-Syndrom. *Z Kardiol* 1997;86:215-57.
 30. Faury G, Pezet M, Knutsen RH, et al. Developmental adaptation of the mouse cardiovascular system to elastin haploinsufficiency. *J Clin Invest* 2003;112:1419-28.
 31. Wessel A, Gravenhorst V, Buchhorn R, Gosch A, Partsch CJ, Pankau R. Risk of sudden death in the Williams-Beuren syndrome. *Am J Med Genet A* 2004;127A:234-7.
 32. Sforzini C, Milani D, Fossali E, et al. Renal tract ultrasonography and calcium homeostasis in Williams-Beuren syndrome. *Pediatr Nephrol* 2002;17:899-902.
 33. Amenta S, Sofocleous C, Kolialexi A, et al. Clinical manifestations and molecular investigation of 50 patients with Williams syndrome in the Greek population. *Pediatr Res* 2005;57:789-95.
 34. Wang MS, Schinzel A, Kotzot D, et al. Molecular and clinical correlation study of Williams-Beuren syndrome: no evidence of molecular factors in the deletion region or imprinting affecting clinical outcome. *Am J Med Genet* 1999;86:34-43.
 35. Pérez Jurado LA, Peoples R, Kaplan P, Hamel BC, Francke U. Molecular definition of the chromosome 7 deletion in Williams syndrome and parent-of-origin effects on growth. *Am J Hum Genet* 1996;59:781-92.
 36. Morris CA, Leonard CO, Dilts C, Demsey SA. Adults with Williams syndrome. *Am J Med Genet Suppl* 1990;6:102-7.
 37. Cagle AP, Waguespack SG, Buckingham BA, Shankar RR, Dimeglio LA. Severe infantile hypercalcemia associated with Williams syndrome successfully treated with intravenously administered pamidronate. *Pediatrics* 2004;114:1091-5.
 38. Cote G, Jequier S, Kaplan P. Increased renal medullary echogenicity in patients with Williams syndrome. *Pediatr Radiol* 1989;19:481-3.
 39. Pober BR, Lacro RV, Rice C, Mandell V, Teele RL. Renal findings in 40 individuals with Williams syndrome. *Am J Med Genet* 1993;46:271-4.
 40. Pankau R, Partsch CJ, Winter M, Gosch A, Wessel A. Incidence and spectrum of renal abnormalities in Williams-Beuren syndrome. *Am J Med Genet* 1996;63:301-4.
 41. Forfar JO, Balf CL, Maxwell GM, Tompsett SL. Idiopathic hypercalcaemia of infancy: clinical and metabolic studies with special reference to the aetiological role of vitamin D. *Lancet* 1956;270:981-8.
 42. Garabedian M, Jacqz E, Guillozo H, et al. Elevated plasma 1,25-dihydroxyvitamin D concentrations in infants with hypercalcemia and an elfin facies. *N Engl J Med* 1985;312:948-52.
 43. Culler FL, Jones KL, Deftos LJ. Impaired calcitonin secretion in patients with Williams syndrome. *J Pediatr* 1985;107:720-3.
 44. Cherniske EM, Carpenter TO, Klaiman C, et al. Multisystem study of 20 older adults with Williams syndrome. *Am J Med Genet A* 2004;131:255-64.
 45. Tyler CV Jr, Snyder CW, Zyzanski S. Screening for osteoporosis in community-dwelling adults with mental retardation. *Ment Retard* 2000;38:316-21.
 46. Knowler WC, Pettitt DJ, Saad MF, Bennett PH. Diabetes mellitus in the Pima Indians: incidence, risk factors and pathogenesis. *Diabetes Metab Rev* 1990;6:1-27.
 47. Stagi S, Bindi G, Neri AS, et al. Thyroid function and morphology in patients affected by Williams syndrome. *Clin Endocrinol (Oxf)* 2005;63:456-60.
 48. Cambiaso P, Orazi C, Digilio MC, et al. Thyroid morphology and subclinical hypothyroidism in children and adolescents with Williams syndrome. *J Pediatr* 2007;150:62-5.
 49. Partsch CJ, Dreyer G, Gosch A, et al. Longitudinal evaluation of growth, puberty, and bone maturation in children with Williams syndrome. *J Pediatr* 1999;134:82-9.
 50. Pankau R, Partsch CJ, Gosch A, Oppermann HC, Wessel A. Statural growth in Williams-Beuren syndrome. *Eur J Pediatr* 1992;151:751-5.
 51. Martin ND, Smith WR, Cole TJ, Preece MA. New height, weight and head circumference charts for British children with Williams syndrome. *Arch Dis Child* 2007;92:598-601.
 52. Meyer-Lindenberg A, Mervis CB,berman KF. Neural mechanisms in Williams syndrome: a unique window to genetic influences on cognition and behaviour. *Nat Rev Neurosci* 2006;7:380-93.
 53. Martens MA, Wilson SJ, Reutens DC.

- Williams syndrome: a critical review of the cognitive, behavioral, and neuroanatomical phenotype. *J Child Psychol Psychiatry* 2008;49:576-608.
54. Mervis CB, Robinson BF, Bertrand J, Morris CA, Klein-Tasman BP, Armstrong SC. The Williams syndrome cognitive profile. *Brain Cogn* 2000;44:604-28.
 55. Udwin O, Davies M, Howlin P. A longitudinal study of cognitive abilities and educational attainment in Williams syndrome. *Dev Med Child Neurol* 1996;38:1020-9.
 56. Fisch GS, Carpenter N, Howard-Peebles PN, et al. Studies of age-correlated features of cognitive-behavioral development in children and adolescents with genetic disorders. *Am J Med Genet A* 2007;143A:2478-89.
 57. Devenny DA, Krinsky-McHale SJ, Kitzler PM, Flory M, Jenkins E, Brown WT. Age-associated memory changes in adults with Williams syndrome. *Dev Neuropsychol* 2004;26:691-706.
 58. Davies M, Udwin O, Howlin P. Adults with Williams syndrome: preliminary study of social, emotional and behavioural difficulties. *Br J Psychiatry* 1998;172:273-6.
 59. Leyfer OT, Woodruff-Borden J, Klein-Tasman BP, Fricke JS, Mervis CB. Prevalence of psychiatric disorders in 4 to 16-year-olds with Williams syndrome. *Am J Med Genet B Neuropsychiatr Genet* 2006;141B:615-22.
 60. Dykens EM. Anxiety, fears, and phobias in persons with Williams syndrome. *Dev Neuropsychol* 2003;23:291-316.
 61. Hopyan T, Dennis M, Weksberg R, Cytrynbaum C. Music skills and the expressive interpretation of music in children with Williams-Beuren syndrome: pitch, rhythm, melodic imagery, phrasing, and musical affect. *Child Neuropsychol* 2001;7:42-53.
 62. Gothelf D, Farber N, Raveh E, Apter A, Attias J. Hyperacusis in Williams syndrome: characteristics and associated neuroaudiologic abnormalities. *Neurology* 2006;66:390-5.
 63. Reiss AL, Eliez S, Schmitt JE, et al. IV. Neuroanatomy of Williams syndrome: a high-resolution MRI study. *J Cogn Neurosci* 2000;12:Suppl 1:65-73.
 64. Pober BR, Filiano JJ. Association of Chiari I malformation and Williams syndrome. *Pediatr Neurol* 1995;12:84-8.
 65. Ferrero GB, Biamino E, Sorasio L, et al. Presenting phenotype and clinical evaluation in a cohort of 22 Williams-Beuren syndrome patients. *Eur J Med Genet* 2007;50:327-37.
 66. Chapman CA, du Plessis A, Pober BR. Neurologic findings in children and adults with Williams syndrome. *J Child Neurol* 1996;11:63-5.
 67. Gagliardi C, Martelli S, Burt MD, Boratti R. Evolution of neurologic features in Williams syndrome. *Pediatr Neurol* 2007;36:301-6.
 68. Meyer-Lindenberg A, Kohn P, Mervis CB, et al. Neural basis of genetically determined visuospatial construction deficit in Williams syndrome. *Neuron* 2004;43:623-31.
 69. Meyer-Lindenberg A, Hariri AR, Munoz KE, et al. Neural correlates of genetically abnormal social cognition in Williams syndrome. *Nat Neurosci* 2005;8:991-3.
 70. Pérez Jurado AL. Williams-Beuren syndrome: a model of recurrent genomic mutation. *Horm Res* 2003;59:Suppl 1:106-13.
 71. Del Campo M, Antonell A, Magano LF, et al. Hemizygosity at the NCF1 gene in patients with Williams-Beuren syndrome decreases their risk of hypertension. *Am J Hum Genet* 2006;78:533-42.
 72. Morris CA. Genotype-phenotype correlations in Williams-Beuren syndrome. In: Morris CA, Lenhoff HM, Wang PP, eds. Williams-Beuren syndrome: research, evaluation, and treatment. Baltimore: Johns Hopkins University Press, 2006:59-82.
 73. van Hagen JM, van der Geest JN, van der Giessen RS, et al. Contribution of CYLN2 and GTF2IRD1 to neurological and cognitive symptoms in Williams syndrome. *Neurobiol Dis* 2007;26:112-24.
 74. Howald C, Merla G, Digilio MC, et al. Two high throughput technologies to detect segmental aneuploidies identify new Williams-Beuren syndrome patients with atypical deletions. *J Med Genet* 2006;43:266-73.
 75. Marshall CR, Young EJ, Pani AM, et al. Infantile spasms is associated with deletion of the MAGI2 gene on chromosome 7q11.23-q21.11. *Am J Hum Genet* 2008;83:106-11.
 76. Somerville MJ, Mervis CB, Young EJ, et al. Severe expressive-language delay related to duplication of the Williams-Beuren locus. *N Engl J Med* 2005;353:1694-701.
 77. Van der Aa N, Rooms L, Vandeweyer G, et al. Fourteen new cases contribute to the characterization of the 7q11.23 microduplication syndrome. *Eur J Med Genet* 2009;52:94-100.
 78. Tam E, Young EJ, Morris CA, et al. The common inversion of the Williams-Beuren syndrome region at 7q11.23 does not cause clinical symptoms. *Am J Med Genet A* 2008;146A:1797-806.
 79. Scherer SW, Gripp KW, Lucena J, et al. Observation of a parental inversion variant in a rare Williams-Beuren syndrome family with two affected children. *Hum Genet* 2005;117:383-8.
 80. Osborne LR, Li M, Pober B, et al. A 1.5 million-base pair inversion polymorphism in families with Williams-Beuren syndrome. *Nat Genet* 2001;29:321-5.
 81. Cuscó I, Corominas R, Bayés M, et al. Copy number variation at the 7q11.23 segmental duplications is a susceptibility factor for the Williams-Beuren syndrome deletion. *Genome Res* 2008;18:683-94.
 82. Li HH, Roy M, Kuscuglu U, et al. Induced chromosome deletions cause hypersociability and other features of Williams-Beuren syndrome in mice. *EMBO Mol Med* 2009;1:50-65.
 83. Schubert C. The genomic basis of the Williams-Beuren syndrome. *Cell Mol Life Sci* 2009;66:1178-97.
 84. Merla G, Howald C, Henrichsen CN, et al. Submicroscopic deletion in patients with Williams-Beuren syndrome influences expression levels of the nonhemizygous flanking genes. *Am J Hum Genet* 2006;79:332-41.
 85. Kaplan P. The medical management of children with Williams-Beuren syndrome. In: Morris CA, Lenhoff HM, Wang PP, eds. Williams-Beuren syndrome: research, evaluation, and treatment. Baltimore: Johns Hopkins University Press, 2006:83-106.
 86. Pober BR. Evidence-based medical management of adults with Williams-Beuren syndrome. In: Morris CA, Lenhoff HM, Wang PP, eds. Williams-Beuren syndrome: research, evaluation, and treatment. Baltimore: Johns Hopkins University Press, 2006:125-43.
 87. Pober BR, Morris CA. Diagnosis and management of medical problems in adults with Williams-Beuren syndrome. *Am J Med Genet C Semin Med Genet* 2007;145C:280-90.
 88. Morris C. Williams syndrome. In: Cassidy SB, Allanson JE, eds. Management of genetic syndromes. Hoboken, NJ: John Wiley & Sons, 2005:655-66.
 89. Lashkari A, Smith AK, Graham JM Jr. Williams-Beuren syndrome: an update and review for the primary physician. *Clin Pediatr (Phila)* 1999;38:189-208.
 90. Geggel RL, Gauvreau K, Lock JE. Balloon dilation angioplasty of peripheral pulmonary stenosis associated with Williams syndrome. *Circulation* 2001;103:2165-70.
 91. Stamm C, Friehs I, Ho SY, Moran AM, Jonas RA, del Nido PJ. Congenital supra-valvar aortic stenosis: a simple lesion? *Eur J Cardiothorac Surg* 2001;19:195-202.
 92. Mookerjee J, Roebuck D, Derrick G. Restenosis after aortic stenting. *Cardiol Young* 2004;14:210-1.
 93. Partsch CJ, Japing I, Siebert R, et al. Central precocious puberty in girls with Williams syndrome. *J Pediatr* 2002;141:441-4.
 94. Reiss JG, Gibson RW, Walker LR. Health care transition: youth, family, and provider perspectives. *Pediatrics* 2005;115:112-20.

Copyright © 2010 Massachusetts Medical Society.