

CASE RECORDS of the MASSACHUSETTS GENERAL HOSPITAL

Founded by Richard C. Cabot  
Eric S. Rosenberg, M.D., *Editor*  
Virginia M. Pierce, M.D., David M. Dudzinski, M.D., Meridale V. Baggett, M.D.,  
Dennis C. Sgroi, M.D., Jo-Anne O. Shepard, M.D., *Associate Editors*  
Kathy M. Tran, M.D., *Case Records Editorial Fellow*  
Emily K. McDonald, Sally H. Ebeling, *Production Editors*



## Case 34-2019: A 16-Year-Old Boy with Jaundice

Brian K. Alverson, M.D., Aoife Kilcoyne, M.D., Alison M. Friedmann, M.D.,  
and Aliyah R. Sohani, M.D.

### PRESENTATION OF CASE

*Dr. Akash Gupta* (Pediatrics): A 16-year-old boy was admitted to this hospital in autumn because of jaundice and abnormal results on liver-function tests.

The patient had been well until 4 days before admission, when he noted pruritus around his ankles. That night, malaise and mild, intermittent, cramping pain in the right upper quadrant developed. The next day, the patient felt fatigued, his appetite was reduced, and the pruritus became diffuse. Two days before admission, he spent much of the day lying on the couch because of fatigue and malaise; he also reported that food tasted “funny,” that his urine appeared darker than usual, and that his mother had told him he appeared pale. The day before admission, the patient continued to feel unwell but went to school, where he was told by a teacher that his skin appeared yellow, which prompted him to present to the school nurse. After a discussion with the patient’s mother and pediatrician, the patient was referred to the emergency department at another hospital for evaluation.

At the other hospital, the patient reported that his stool had appeared pale gray that day. On examination, the temperature was 36.7°C, the pulse 102 beats per minute, the blood pressure 139/82 mm Hg, the respiratory rate 20 breaths per minute, and the oxygen saturation 98% while the patient was breathing ambient air. The patient did not appear ill but had conjunctival icterus and jaundiced skin. There was no abdominal tenderness, and the remainder of the physical examination was normal. The red-cell indexes and blood levels of electrolytes, glucose, amylase, and lipase were normal, as were the results of renal-function tests; other laboratory test results are shown in Table 1. Urinalysis showed clear, amber urine, with a moderate amount of bilirubin, trace albumin, a specific gravity of 1.018, and a pH of 5.5 by dipstick testing. A blood test for heterophile antibodies was negative, as were blood tests for hepatitis A virus IgM antibodies, hepatitis B virus surface antigen, hepatitis B virus core IgM antibodies, and hepatitis C virus anti-

From the Department of Pediatrics, Warren Alpert Medical School of Brown University, Providence, RI (B.K.A.); and the Departments of Radiology (A.K.), Pediatrics (A.M.F.), and Pathology (A.R.S.), Massachusetts General Hospital, and the Departments of Radiology (A.K.), Pediatrics (A.M.F.), and Pathology (A.R.S.), Harvard Medical School — both in Boston.

N Engl J Med 2019;381:1763-72.

DOI: 10.1056/NEJMcpc1904047

Copyright © 2019 Massachusetts Medical Society.

**Table 1. Laboratory Data.\***

Variable	Reference Range, Other Hospital	On Presentation, Other Hospital	Reference Range, This Hospital†	On Presentation, This Hospital
Hemoglobin (g/dl)	12.0–16.0	12.2	13.0–16.0	11.4
Hematocrit (%)	36–49	36	37.0–49.0	33.2
White-cell count (per $\mu$ l)	4500–13,000	700	4500–13,000	900
Differential count (%)				
Neutrophils		20		
Lymphocytes		64		
Monocytes		8		
Atypical lymphocytes		8		
Platelet count (per $\mu$ l)	150,000–400,000	95,000	150,000–450,000	92,000
Red-cell count (per $\mu$ l)	4,100,000–5,100,000	4,090,000	4,500,000–5,300,000	4,030,000
Prothrombin time (sec)			11.0–14.0	16.1
Prothrombin-time international normalized ratio			0.9–1.1	1.3
Protein (mg/dl)				
Total	6.1–8.2	6.1	6.0–8.3	5.8
Albumin	3.4–5.0	3.8	3.3–5.0	4.1
Globulin	2.5–4.3	2.3	1.9–4.1	1.7
Alanine aminotransferase (U/liter)	0–55	3058	10–55	2839
Aspartate aminotransferase (U/liter)	15–37	1664	10–40	1751
Alkaline phosphatase (U/liter)	52–171	297	15–350	299
$\gamma$ -Glutamyltransferase (U/liter)	12–64	140	8–61	104
Bilirubin (mg/dl)				
Total	0.2–1.2	8.5	0–1.0	8.1
Direct	0.0–0.5	6.3	0–0.4	5.7
Ceruloplasmin (mg/dl)			20–43	49

\* To convert the values for bilirubin to micromoles per liter, multiply by 17.1.

† Reference values are affected by many variables, including the patient population and the laboratory methods used. The ranges used at Massachusetts General Hospital are for adults who are not pregnant and do not have medical conditions that could affect the results. They may therefore not be appropriate for all patients.

bodies. After discussion with a pediatric gastroenterologist, the patient was transferred to the emergency department of this hospital.

On arrival, the patient rated his abdominal pain at 6 on a scale of 0 to 10, with 10 indicating the most severe pain. He had undergone tonsillectomy in the remote past. He had never received a blood transfusion. He took no medications or herbal or dietary supplements and had no known allergies; immunizations were reportedly up to date. The patient lived with his parents and two dogs in a heavily forested, rural area of

New England and had not traveled recently. Five days before the onset of illness, he had eaten at a fast-food restaurant. He had had no known exposure to sick persons, was not sexually active, and did not smoke cigarettes, drink alcohol, or use illicit drugs. One year earlier, the patient's mother had undergone a medical evaluation because of fatigue and jaundice and had been found to have abnormally elevated results of liver-function tests; no specific diagnosis was made, and the illness resolved spontaneously. His maternal grandfather had a history of nonalcoholic fatty

liver disease and brain cancer. A maternal second cousin had systemic lupus erythematosus.

On examination, the patient appeared jaundiced but not ill. The temperature was 36.8°C, the pulse 80 beats per minute, the blood pressure 134/59 mm Hg, the respiratory rate 20 breaths per minute, and the oxygen saturation 99% while he was breathing ambient air. The weight was 76.5 kg. There was mild tenderness in the right upper quadrant; evaluation for hepatomegaly and splenomegaly was limited because the patient was ticklish. The remainder of the physical examination was unchanged. The red-cell indexes, activated partial-thromboplastin time, anion gap, and blood levels of electrolytes, glucose, lipase, and acetaminophen were normal, as were the results of renal-function tests; other laboratory test results are shown in Table 1. Urinalysis showed clear, amber urine, with 1+ bilirubin, 1+ urobilinogen, a specific gravity of 1.010, and a pH of 6.0 by dipstick testing. Blood was tested for human immunodeficiency virus type 1 RNA, as well as for Epstein-Barr virus (EBV) antibodies, cytomegalovirus antibodies, *Borrelia burgdorferi* antibodies, antinuclear antibodies, antimitochondrial antibodies, anti-smooth muscle antibodies, and anti-liver-kidney microsomal type 1 antibodies.

*Dr. Aoife Kilcoyne:* Ultrasonography of the abdomen revealed mild, diffuse heterogeneous echotexture of the liver. No intrahepatic or extrahepatic biliary ductal dilatation was noted. The gallbladder was contracted, with no pericholecystic fluid. There was no ascites. The spleen was enlarged, measuring up to 16.2 cm in the craniocaudal dimension (normal length, <13 cm)<sup>1</sup> (Fig. 1). No focal splenic lesions were observed. Doppler evaluation of the upper abdominal vasculature was normal.

*Dr. Gupta:* While the patient was in the emergency department, the abdominal pain decreased. Intravenous fluids were administered, and, early the next morning, the patient was admitted to the hospital.

On admission, the patient reported mild, diffuse pruritus, which was most prominent on the upper back, and mild, diffuse abdominal pain. There was no pharyngeal erythema or exudate and no cervical, supraclavicular, axillary, or inguinal lymphadenopathy; the remainder of the physical examination was unchanged. The pa-

tient received treatment with oral ursodiol and vitamin E and intramuscular vitamin K.

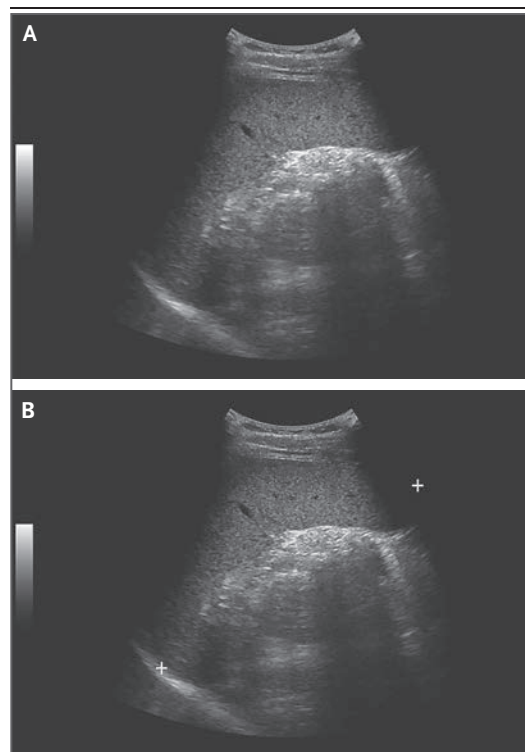
Additional diagnostic tests were performed, and a diagnosis was made.

#### DIFFERENTIAL DIAGNOSIS

*Dr. Brian K. Alverson:* This 16-year-old boy, who has no clinically significant medical history, presents with acute hepatitis, hyperbilirubinemia, leukopenia, lymphopenia, and thrombocytopenia. There are several aspects of his history, findings on physical examination, and laboratory test results that inform my differential diagnosis.

#### TOXIN-MEDIATED DISEASE

In any previously well adolescent presenting with acute hepatitis and conjugated hyperbilirubinemia, toxin-mediated diseases must be considered. A normal acetaminophen level does not



**Figure 1. Abdominal Ultrasound Images.**

Grayscale ultrasound images (Panels A and B) show an enlarged spleen, measuring up to 16.2 cm (normal length, <13 cm).

always rule out the possibility of drug-related toxic effects, since long-term administration can cause hepatitis through reduction of glutathione stores. However, acetaminophen does not cause alteration of cell lines in the complete blood count; therefore, disease resulting from the use of acetaminophen is an unlikely diagnosis in this case.

In rare cases, severe acute hepatitis can be caused by use of the recreational drug “ecstasy” (3,4-methylenedioxyamphetamine); in this case, it could be caused by ingestion of the wild mushroom *Amanita pantherina*, given that the patient lives in a wooded area in New England. However, these two toxins, like acetaminophen, do not cause neutropenia or thrombocytopenia.

#### INHERITED DISEASE

One important aspect of this case is the family history of liver disease, which suggests the possibility that an inherited condition may be contributing to this patient’s illness. The cause of his mother’s hepatitis was never elucidated, and his maternal grandfather reportedly had nonalcoholic fatty liver disease.

Two familial conditions — the Dubin–Johnson syndrome and the Rotor syndrome — are associated with intermittent-transient conjugated hyperbilirubinemia.<sup>2</sup> These syndromes are typically benign and manifest with periodic hyperbilirubinemia but do not manifest with decreased cell counts or with elevated aminotransferase levels. Pruritus is also uncommon in these conditions.

Wilson’s disease is an inherited disease that can cause conjugated hyperbilirubinemia and hepatosplenomegaly. However, in patients with Wilson’s disease, hepatitis would not typically resolve spontaneously (as it did in the patient’s mother) and would usually manifest earlier in life; hepatitis is unlikely to be confused with nonalcoholic fatty liver disease, which was diagnosed in this patient’s grandfather. Bone marrow is not affected in patients with Wilson’s disease, so this disease can reasonably be ruled out on the basis of family history and laboratory findings. The ceruloplasmin level was essentially normal; however, ceruloplasmin is an acute-phase reactant and can be normal in patients with Wilson’s disease who also have acute inflammatory disease.<sup>3</sup>

An underlying diagnosis of the MZ phenotype

of  $\alpha_1$ -antitrypsin deficiency, which is the “carrier state” for the condition, is a consideration in this case. Patients are often not asymptomatic but are more likely to have hepatitis in the context of concurrent illness (particularly viral hepatitis).<sup>4</sup> However, the absence of a family history of lung disease (e.g., chronic obstructive pulmonary disease or asthma) makes this diagnosis unlikely.<sup>5</sup> Although this condition is probably not the underlying problem in this patient, his family may benefit from genetic testing for the condition, especially if hepatitis develops in additional family members.

#### INFECTION

Hepatitis A, B, and C viruses were ruled out by serologic testing; however, several other viruses can cause acute hepatitis, including EBV, cytomegalovirus, parvovirus, hepatitis E virus, enterovirus, and adenovirus. Heterophile antibodies, which would suggest acute EBV infection, were not detected, but the test for these antibodies is often negative early in the course of disease.

In addition to causing hepatitis and splenomegaly, EBV is associated with bone marrow suppression, often through the development of hemophagocytic lymphohistiocytosis (HLH). This syndrome results from excessive activation of the immune system and is associated with a variety of underlying genetic mutations. Macrophages will inappropriately phagocytize other cell lines in the bone marrow, probably through decreased inactivation of natural killer cells and cytotoxic lymphocytes. Because there is no clear single diagnostic test, the diagnosis of HLH is made if a patient meets five of eight clinical criteria; however, some affected patients present with fewer than five criteria.<sup>6</sup> This patient met two criteria for HLH — splenomegaly and low cell counts for two cell lines — but several laboratory criteria were not evaluated. He did not have many findings on physical examination that would be consistent with HLH and EBV infection. He had no fever, pharyngitis, or lymphadenopathy; fever is almost always present in patients with HLH.<sup>7</sup> I would obtain a blood sample to measure the ferritin level as an inexpensive partial workup for HLH. A ferritin level below 500 mg per liter would probably point us away from a diagnosis of HLH. There is great

variability in the clinical presentation of HLH, and a rapid diagnosis improves a patient's prognosis; therefore, a high clinical suspicion and early testing is indicated.

This patient lives in a wooded area in New England, which raises the possibility of a tick-borne illness. Although antibody testing for *B. burgdorferi* was performed, this patient's presentation is not consistent with Lyme disease, which is typically characterized by rash, facial palsy, meningitis, or heart block, and later, arthritis. Testing for Lyme disease should be discouraged in cases such as this one, because false positive results are common and can be misleading.<sup>8</sup> Furthermore, false positive results are particularly common in the context of acute EBV infection, which remains a possible diagnosis for this patient.

Human granulocytic anaplasmosis, which is caused by *Anaplasma phagocytophilum*, is the second most common rickettsial infection in the United States and is prevalent in New England.<sup>9</sup> This disease is usually less clinically severe than Rocky Mountain spotted fever; however, one third of affected patients require hospitalization, and death may occur.<sup>10</sup> Presentation with thrombocytopenia, leukopenia, and elevated aminotransferase levels is typical for human granulocytic anaplasmosis, but signs and symptoms of the disease can be highly variable. However, this patient has no fever, headache, myalgia, or arthralgia, all of which are common features of this disease. It would not be unreasonable to perform blood nucleic acid testing for anaplasma, and, if there is a delay in definitive diagnosis, it would be prudent to initiate therapy with doxycycline, because a delay in treatment increases the risk of death.<sup>10</sup> Rocky Mountain spotted fever may manifest with laboratory findings that are similar to those of anaplasmosis; however, affected patients are typically febrile and appear much more ill than this patient, and a majority of patients have a rapidly progressive petechial rash.

#### AUTOIMMUNE HEPATITIS

It was appropriate that the physicians caring for this patient were concerned about the possibility of autoimmune hepatitis, which can be associated with aplastic anemia. Hepatitis-associated aplastic anemia is the cause of approximately

2 to 5% of cases of childhood aplastic anemia.<sup>11</sup> In adults, hepatitis-associated aplastic anemia typically occurs well after the onset of jaundice, but in adolescents, this condition can manifest concurrently. This condition is characterized by acute hepatitis, conjugated hyperbilirubinemia, and cytopenia. This patient's remote family history of autoimmune disease, as well as his afebrile presentation, would be consistent with hepatitis-associated aplastic anemia. In addition, although autoimmune antibodies are typically detected in the context of autoimmune hepatitis, these tests may be negative in patients with hepatitis-associated aplastic anemia. Thus, this patient's normal blood globulin level does not rule out the disease.

There are two features of this patient's presentation that render the diagnosis of hepatitis-associated aplastic anemia unlikely. First, he has splenomegaly, which is probably not due to hepatomegaly, given that he has normal abdominal vasculature on ultrasonography. Second, the hemoglobin level is not declining as rapidly as I would expect if this patient had hepatitis-associated aplastic anemia, although in patients with aplastic anemia, the anemia may manifest later than neutropenia or thrombocytopenia, and the second complete blood count reported in this patient may represent an early downward trend.

#### CANCER

Patients with hepatosplenic T-cell lymphoma may present with findings similar to those seen in this patient, including the absence of lymphadenopathy and the presence of hepatic abnormalities and cytopenia.<sup>12,13</sup> However, this condition is rare and occurs more commonly in immunosuppressed patients than in immunocompetent ones.

The most likely diagnosis in this case is acute leukemia. Acute hepatitis without liver failure is a rare but well-recognized manifestation of acute childhood leukemia.<sup>14</sup> Patients may present with hepatosplenomegaly and without lymphadenopathy. Conjugated hyperbilirubinemia and elevated aminotransferase levels occur in patients who present with jaundice, and typically, patients have low cell counts for multiple cell lines in a complete blood count. Blasts may be scant or absent on a peripheral-blood smear. The

atypical lymphocytes reported by the laboratory at the other hospital may have actually been blasts that were misidentified. To establish the diagnosis of acute leukemia in this patient, I would recommend a bone marrow aspiration and biopsy.

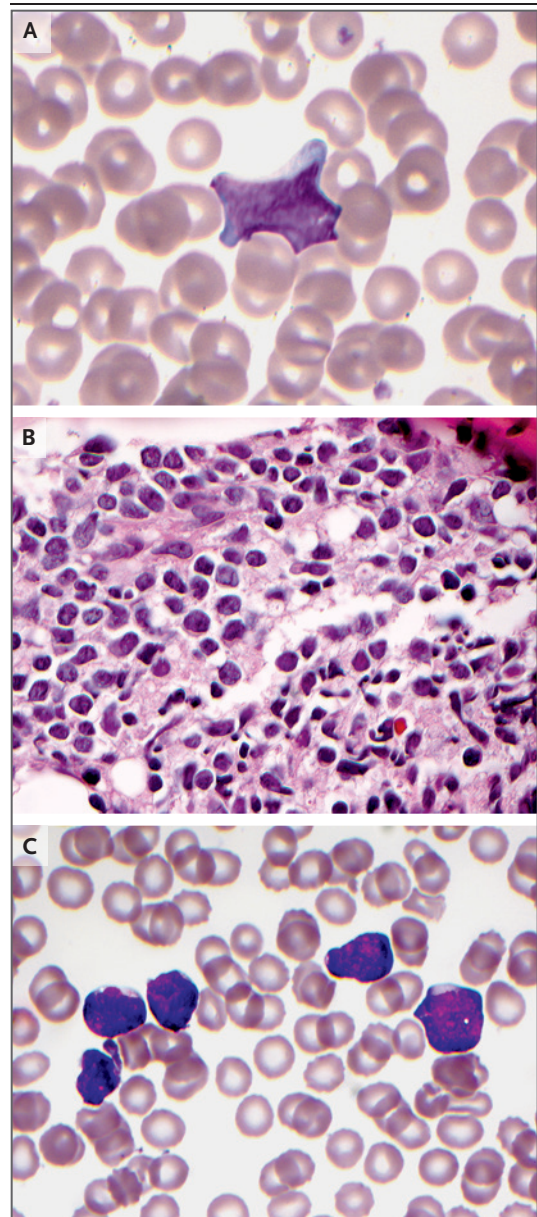
DR. BRIAN K. ALVERSON'S  
DIAGNOSIS

Acute leukemia.

PATHOLOGICAL DISCUSSION

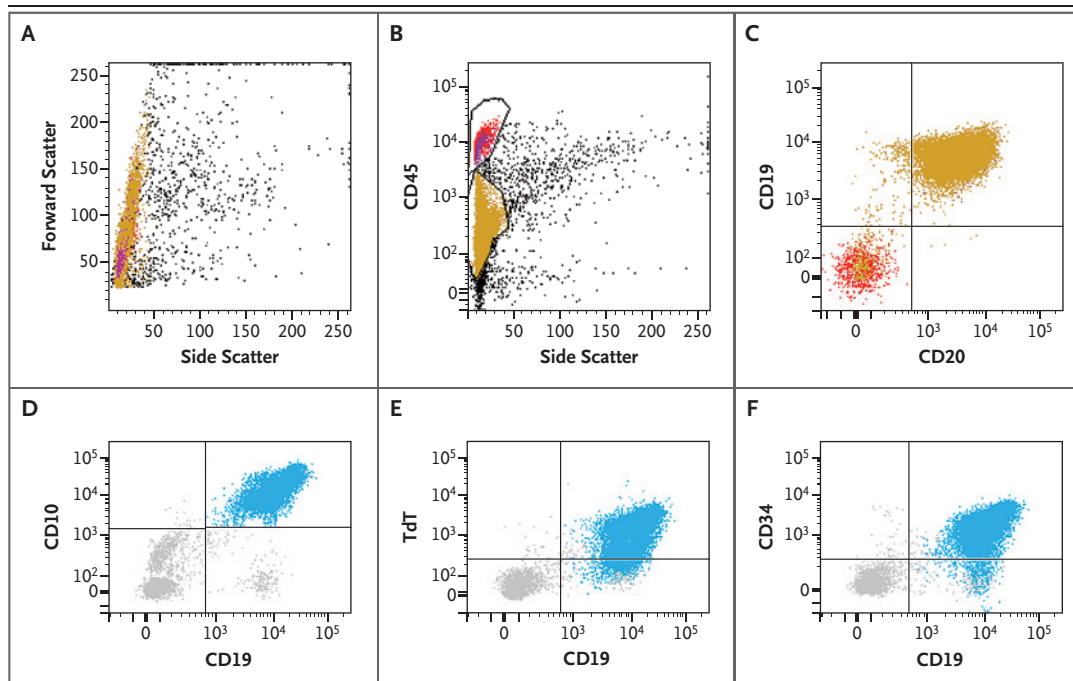
*Dr. Aliyah R. Sohani:* The white-cell differential count obtained on presentation to this hospital showed marked neutropenia, lymphocytic predominance, and 9% blasts (Fig. 2A); these findings probably corresponded to the atypical lymphocyte population noted in the differential count obtained at the other hospital. The presence of blasts was confirmed by means of flow cytometry of the peripheral blood, which identified a small population of B lymphoid blasts that showed dim expression of CD45 and expression of CD19, CD20, CD10, CD34, and terminal deoxynucleotidyl transferase (TdT) and which was negative for surface kappa and lambda immunoglobulin light chains.

A bone marrow biopsy and aspiration were performed the next day. The bone marrow core biopsy specimen was highly cellular, with decreased normal hematopoietic elements. Approximately 95% of the marrow cells consisted of blasts (Fig. 2B and 2C), and flow cytometry of the bone marrow aspirate showed B lymphoid blasts that were immunophenotypically identical to the circulating blasts (Fig. 3). Bone marrow cytogenetic analysis showed the following complex karyotype containing two related clones, each with deletions or rearrangements that resulted in loss of the short (p) arm of chromosome 9 in 19 of 20 metaphases: 46,XY,del(9)(p13),i(9)(q10)[cp2]/46,XY,del(3)(q21),t(6;9)(q21;p22),i(9)(q10)[cp17]/46,XY[1]. Fluorescence in situ hybridization confirmed the loss of chromosome 9p in 92% of interphase nuclei, an abnormality that is reported to be more common among patients with childhood acute lymphoblastic leukemia (ALL) who have high-risk clinical features than among those with childhood ALL who do not have high-risk



**Figure 2. Specimens of Peripheral Blood and Bone Marrow.**

Wright–Giemsa staining of a peripheral-blood smear (Panel A) shows evidence of pancytopenia, with a small population of enlarged cells with irregular nuclei, dispersed chromatin, and scant cytoplasm, findings that are morphologically consistent with blasts. On hematoxylin and eosin staining of a core biopsy specimen of the bone marrow (Panel B), the specimen is hypercellular for the patient's age, with a near absence of normal hematopoietic precursors. Most of the cells seen in the core biopsy specimen and on Wright–Giemsa staining in the aspirate smear (Panel C) are medium in size, with round-to-irregular nuclei, dispersed chromatin, scant cytoplasm, and small nucleoli, findings that are consistent with blasts.



**Figure 3.** Flow Cytometric Studies of the Bone Marrow Aspirate.

The abnormal blast population is shown in gold (Panels A, B, and C) and in blue (Panels D, E, and F). On light-scatter analysis (Panel A), the blasts have greater forward scatter than normal small lymphocytes (shown in magenta), a finding that is indicative of their larger size relative to normal lymphocytes. The blasts show dim expression of CD45 (leukocyte common antigen) (Panel B); are positive for B-cell markers CD19 and CD20 (Panel C); are positive for CD10 (Panel D); are positive for markers of immaturity, terminal deoxynucleotidyl transferase (TdT) (Panel E) and CD34 (Panel F); and lack expression of kappa and lambda immunoglobulin light chains (not shown).

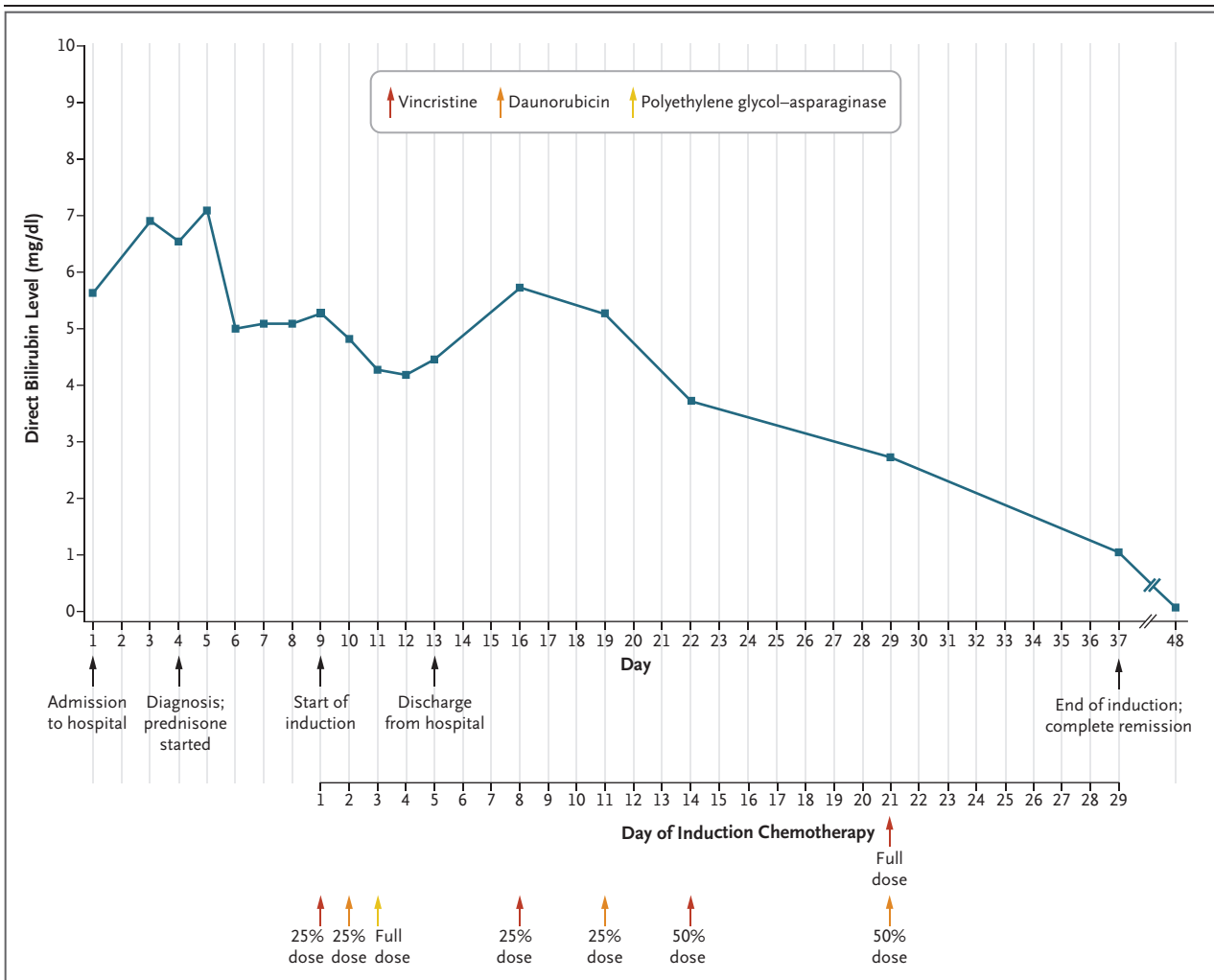
clinical features.<sup>15</sup> The bone marrow specimen was sent to a reference laboratory; a multiplex reverse-transcriptase–polymerase-chain-reaction (RT-PCR) assay did not detect fusions involving *ABL1* or other kinase genes that result in an RNA expression profile that is similar to that of B-cell ALL with *BCR-ABL1* rearrangement.<sup>16,17</sup>

#### DISCUSSION OF MANAGEMENT

*Dr. Alison M. Friedmann:* When I first met this young man, he was afebrile and appeared well, with mild jaundice. The confirmation of the presence of B lymphoid blasts on flow cytometry of the peripheral blood prompted the bone marrow examination as well as a lumbar puncture and administration of intrathecal cytarabine. I considered the patient to have very-high-risk B-cell ALL on the basis of his age.

The next step in the management of this patient's illness was induction chemotherapy; the

national standard of care includes four drugs: prednisone, vincristine, daunorubicin, and polyethylene glycol–asparaginase. However, the presence of hepatitis and clinically significant cholestasis limited the use of some of these medications initially. Measurement of direct bilirubin is generally considered to be the most useful marker of biliary clearance, and the value is used to guide decisions regarding the administration and dosage of chemotherapeutic agents that are cleared through biliary excretion. Among the standard induction chemotherapeutic agents, both vincristine and daunorubicin are excreted through the biliary tract. Current treatment guidelines from the Children's Oncology Group recommend that daunorubicin be omitted when the direct bilirubin level is greater than 5.0 mg per deciliter (86  $\mu\text{mol}$  per liter) and that vincristine be omitted when the direct bilirubin level is higher than 6.0 mg per deciliter (103  $\mu\text{mol}$  per liter).<sup>18</sup> In addition, the dosages of these agents



**Figure 4. Timeline of the Clinical Course.**

Shown are the timing of chemotherapy and the doses administered, the timing of important clinical events, and the direct bilirubin values starting on the day of admission. On day 29 of induction, bone marrow aspiration revealed a complete morphologic remission (defined as <5% blasts) and no detectable evidence of leukemia on flow cytometry (with negative status for measurable residual disease, defined as <0.01% blasts). To convert the values for bilirubin to micromoles per liter, multiply by 17.1.

should be reduced when the direct bilirubin level is elevated to a lesser degree. An additional concern with respect to initiating induction chemotherapy for this patient was that polyethylene glycol-asparaginase can cause clinically significant hepatotoxic effects; therefore, caution is warranted when administering this drug to patients with preexisting hepatic dysfunction. Because the patient's direct bilirubin level was higher than 7.0 mg per deciliter (120  $\mu$ mol per liter) when the diagnosis of B-cell ALL was estab-

lished, I opted to start the patient's treatment with prednisone alone and to monitor the results of liver-function tests daily to guide decisions regarding the introduction of the other important medications.

The diagnosis of B-cell ALL was established and prednisone was started on hospital day 4 (Fig. 4). Vincristine was started at 25% of the standard dose 5 days later, when the direct bilirubin level had declined from a peak value of 7.1 mg per deciliter (121  $\mu$ mol per liter) to 5.3 mg



per deciliter (91  $\mu\text{mol}$  per liter). Daunorubicin was administered at 25% of the standard dose the next day, and a full dose of polyethylene glycol–asparaginase was administered on hospital day 11, when the direct bilirubin level had declined to 4.3 mg per deciliter (74  $\mu\text{mol}$  per liter). The patient was discharged on hospital day 13; the blood counts were recovering, and induction chemotherapy was continued on an outpatient basis.

Additional doses of vincristine and daunorubicin were administered at reduced doses until day 21 of induction, when a full dose of vincristine was administered, given that the direct bilirubin level had declined to 2.7 mg per deciliter (46  $\mu\text{mol}$  per liter). From the standpoint of assessing the response to therapy, we considered day 1 of induction to be the day the first dose of vincristine was administered.

Peripheral blood was tested for residual leukemia on day 8 and showed 0.7% lymphoid blasts. This test was repeated on day 12 of induction, and the level had decreased to below 0.01%. By day 29 of induction (the final day of induction), the direct bilirubin level had decreased to 1.1 mg per deciliter (19  $\mu\text{mol}$  per liter). Bone marrow aspiration revealed a complete morphologic remission (defined as <5% blasts) and no detectable evidence of leukemia on flow cytometry (with negative status for measurable residu-

al disease [also referred to as minimal residual disease], defined as <0.01% blasts).

Subsequent treatment was based on the treatment administered to patients in the very-high-risk group of the Children's Oncology Group AALL1131 trial (ClinicalTrials.gov number, NCT02883049). The patient was not eligible to enroll in the clinical trial because of his abnormal results on liver-function tests. He was considered to be in a very-high-risk category on the basis of his age at the time of diagnosis. His postinduction treatment was based on a modified Berlin–Frankfurt–Münster chemotherapy regimen, with four cycles of high-dose methotrexate delivered during the first interim maintenance phase and escalating doses of methotrexate delivered during a second interim maintenance phase. Overall, he had no major untoward complications associated with treatment, and he completed the treatment 39 months after diagnosis. Currently, 3 years 10 months after diagnosis, he is well and is in complete remission.

#### ANATOMICAL DIAGNOSIS

##### B-cell acute lymphoblastic leukemia.

This case was presented at the New England Pediatric Hospital Medicine Conference.

Disclosure forms provided by the authors are available with the full text of this article at NEJM.org.

#### REFERENCES

- Rosenberg HK, Markowitz RI, Kolberg H, Park C, Hubbard A, Bellah RD. Normal splenic size in infants and children: sonographic measurements. *AJR Am J Roentgenol* 1991;157:119-21.
- Strassburg CP. Hyperbilirubinemia syndromes (Gilbert-Meulengracht, Crigler-Najjar, Dubin-Johnson, and Rotor syndrome). *Best Pract Res Clin Gastroenterol* 2010;24:555-71.
- Poujois A, Woimant F. Wilson's disease: a 2017 update. *Clin Res Hepatol Gastroenterol* 2018;42:512-20.
- Banner BF, Karamitsios N, Smith L, Bonkovsky HL. Enhanced phenotypic expression of alpha-1-antitrypsin deficiency in an MZ heterozygote with chronic hepatitis C. *Am J Gastroenterol* 1998;93:1541-5.
- Hersh CP, Dahl M, Ly NP, Berkey CS, Nordestgaard BG, Silverman EK. Chronic obstructive pulmonary disease in alpha-1-antitrypsin PI MZ heterozygotes: a meta-analysis. *Thorax* 2004;59:843-9.
- Hayden A, Park S, Giustini D, Lee AYY, Chen LYC. Hemophagocytic syndromes (HPSs) including hemophagocytic lymphohistiocytosis (HLH) in adults: a systematic scoping review. *Blood Rev* 2016;30:411-20.
- Bergsten E, Horne A, Aricó M, et al. Confirmed efficacy of etoposide and dexamethasone in HLH treatment: long-term results of the cooperative HLH-2004 study. *Blood* 2017;130:2728-38.
- Hansmann Y, Leyer C, Lefebvre N, et al. Feedback on difficulties raised by the interpretation of serological tests for the diagnosis of Lyme disease. *Med Mal Infect* 2014;44:199-205.
- Dahlgren FS, Mandel EJ, Krebs JW, Massung RF, McQuiston JH. Increasing incidence of Ehrlichia chaffeensis and Anaplasma phagocytophilum in the United States, 2000-2007. *Am J Trop Med Hyg* 2011;85:124-31.
- Bakken JS, Dumler JS. Human granulocytic anaplasmosis. *Infect Dis Clin North Am* 2015;29:341-55.
- Patel KR, Bertuch A, Sasa GS, Himes RW, Wu H. Features of hepatitis in hepatitis-associated aplastic anemia: clinical and histopathologic study. *J Pediatr Gastroenterol Nutr* 2017;64(1):e7-e12.
- O'Suoi C, Welch JGG, Perkins SL, et al. Rare pediatric non-Hodgkin lymphomas: a report from Children's Oncology Group Study ANHL 04B1. *Pediatr Blood Cancer* 2016;63:794-800.
- Weidmann E. Hepatosplenic T cell lymphoma: a review on 45 cases since the first report describing the disease as a distinct lymphoma entity in 1990. *Leukemia* 2000;14:991-7.
- Rivet C, Leverger G, Jacquemin E, Bernard O. Acute leukemia presenting as acute hepatitis without liver failure. *J Pediatr Gastroenterol Nutr* 2014;59:640-1.
- Murphy SB, Raimondi SC, Rivera GK, et al. Nonrandom abnormalities of chromosome 9p in childhood acute lymphoblastic leukemia: association with high-risk clinical features. *Blood* 1989;74:409-15.

16. Borowitz M, Chan J, Downing J, Le Beau M, Arber D. B-lymphoblastic leukaemia/lymphoma not otherwise specified (NOS). In: Swerdlow S, Campo E, Harris N, et al., eds. WHO classification of tumours of haematopoietic and lymphoid tissues. Lyon, France: International Agency for Research on Cancer, 2017:200-2.
17. Borowitz M, Chan J, Downing J, Le Beau M, Arber D. B-lymphoblastic leukaemia/lymphoma with recurrent genetic abnormalities. In: Swerdlow S, Campo E, Harris N, et al., eds. WHO classification of tumours of haematopoietic and lymphoid tissues. Lyon, France: International Agency for Research on Cancer, 2017:203-9.
18. Floyd J, Mirza I, Sachs B, Perry MC. Hepatotoxicity of chemotherapy. *Semin Oncol* 2006;33:50-67.

Copyright © 2019 Massachusetts Medical Society.

**JOURNAL ARCHIVE AT NEJM.ORG**

Every article published by the *Journal* is now available at NEJM.org, beginning with the first article published in January 1812. The entire archive is fully searchable, and browsing of titles and tables of contents is easy and available to all. Individual subscribers are entitled to free 24-hour access to 50 archive articles per year. Access to content in the archive is available on a per-article basis and is also being provided through many institutional subscriptions.