REVIEW ARTICLE

MEDICAL PROGRESS

Membranoproliferative Glomerulonephritis — A New Look at an Old Entity

Sanjeev Sethi, M.D., Ph.D., and Fernando C. Fervenza, M.D., Ph.D.

Membranoproliferative glomerulonephritis (MPGN), also termed mesangiocapillary glomerulonephritis, is diagnosed on the basis of a glomerular-injury pattern that is common to a heterogeneous group of diseases. MPGN accounts for approximately 7 to 10% of all cases of biopsy-confirmed glomerulonephritis[1-4] and ranks as the third or fourth leading cause of end-stage renal disease among the primary glomerulonephritides.[2,5] Although some diseases associated with MPGN are well known, recent advances have identified additional MPGN-associated conditions.

From the Department of Laboratory Medicine and Pathology (S.S.) and the Department of Internal Medicine, Division of Nephrology and Hypertension (F.C.F.), Mayo Clinic, Rochester, MN. Address reprint requests to Dr. Sethi at the Department of Laboratory Medicine and Pathology, Mayo Clinic, 200 1st St. SW, Rochester, MN 55905, or at sethi.sanjeev@mayo.edu.

N Engl J Med 2012;366:1119-31.
Copyright © 2012 Massachusetts Medical Society.

CLINICAL PRESENTATION

MPGN most commonly presents in childhood but can occur at any age. The clinical presentation and course are extremely variable — from benign and slowly progressive to rapidly progressive. Thus, patients can present with asymptomatic hematuria and proteinuria, the acute nephritic syndrome, the nephrotic syndrome, chronic kidney disease, or even a rapidly progressive glomerulonephritis. The varied clinical presentation is caused by differences in the pathogenesis of the disorder and in the timing of the diagnostic biopsy relative to the clinical course. The degree of kidney impairment also varies, and hypertension may or may not be present. Patients who present early in the disease process, when the kidney biopsy shows proliferative lesions, are more likely to have a nephritic phenotype, and those with crescentic MPGN may present with a rapidly progressive glomerulonephritis. In contrast, patients with biopsies showing advanced changes that include both repair and sclerosis are more likely to have a nephrotic phenotype. Patients with classic MPGN often have features of both the acute nephritic syndrome and the nephrotic syndrome — termed the nephritic–nephrotic phenotype.

CLASSIFICATION AND PATHOPHYSIOLOGY

The typical features of MPGN on light microscopy include mesangial hypercellularity, endocapillary proliferation, and capillary-wall remodeling (with the formation of double contours) — all of which result in lobular accentuation of the glomerular tufts. These changes result from the deposition of immunoglobulins, complement factors, or both in the glomerular mesangium and along the glomerular capillary walls. On the basis of the electron-microscopical findings, MPGN is traditionally classified as primary (idiopathic) MPGN type I (MPGN I), type II (MPGN II), or type III (MPGN III) or secondary MPGN. MPGN I, the most common form, is characterized by subendothelial deposits, and MPGN III has both subepithelial and subendothelial deposits.[6,7] MPGN II is characterized by dense deposits in the glomerular basement membrane

The New England Journal of Medicine
Downloaded from nejm.org by LUIGI GRECO on April 16, 2012. For personal use only. No other uses without permission.
Copyright © 2012 Massachusetts Medical Society. All rights reserved.

("dense-deposit disease"). Secondary MPGN, described by Rennke,[8] is most often due to hepatitis C and other infections.

As currently classified, MPGN I and MPGN III are likely to include cases of both immune-complex–mediated and complement-mediated MPGN. Given recent advances in our understanding of the role of the alternative pathway of complement in MPGN, a practical approach is to view MPGN as immune-complex–mediated or complement-mediated.[9] Thus, immune-complex–mediated MPGN may occur when there are increased levels of circulating immune complexes, and complement-mediated MPGN may occur because of disorders associated with dysregulation of the alternative pathway of complement.

IMMUNE-COMPLEX–MEDIATED MPGN

Immune-complex–mediated MPGN results from the deposition of immune complexes in the glomeruli owing to persistent antigenemia, with antigen-antibody immune complexes forming as a result of chronic infections, elevated levels of circulating immune complexes due to autoimmune diseases, or paraproteinemias due to monoclonal gammopathies. The immune complexes trigger the activation of the classical pathway of complement and the deposition of complement factors of the classical pathway and terminal complement pathway in the mesangium and along the capillary walls (Fig. 1; and Fig. 1 in the Supplementary Appendix, available with the full text of this article at NEJM.org). A kidney-biopsy specimen typically shows immunoglobulin and complement on immunofluorescence microscopy.

HEPATITIS C AND OTHER INFECTIONS

Chronic viral infections such as hepatitis C and hepatitis B, with or without circulating cryoglobulins, are an important cause of MPGN. Hepatitis C, which was recognized as a common cause of immune-complex–mediated MPGN in the 1990s, is now considered to be the main viral infection causing MPGN.[8,10-13] In addition to viral infections, chronic bacterial infections (e.g., endocarditis, shunt nephritis, and abscesses), fungal infections, and parasitic infections are associated with MPGN, particularly in the developing world.[14-18] Bacteria associated with MPGN include staphylococcus, *Mycobacterium tuberculosis*, streptococci, *Propionibacterium acnes*, *Mycoplasma pneumoniae*, brucella, *Coxiella burnetii*, nocardia, and meningococcus.[19-30]

Figure 1 (facing page). Normal Glomerular Capillary Wall and Immune-Complex–Mediated Membranoproliferative Glomerulonephritis (MPGN).

Panel A is a schematic model of the normal glomerular capillary wall, with surface regulators of complement on the endothelial cells and glomerular basement membranes. Panel B is a schematic model of MPGN associated with immune-complex deposition and the activation of the classical pathway. The binding of antibodies results in the activation of C1, which then cleaves C4 and C2 to generate C4b and C2a. These proteins form C4b2a, the classical pathway convertase, resulting in the activation of the C3 convertase and terminal complement complex. The injury phase results from the deposition of immune complexes and complement factors of the classical and terminal pathways. The injury phase is followed by an influx of leukocytes, leading to a proliferative phase, with damage to the capillary walls from the release of cytokines and proteases (labeled P) and ensuing hematuria and proteinuria. The endothelial cells show loss of fenestrations, the glomerular basement is disrupted, and podocytes show effacement of foot processes. Reparative changes follow, with the formation of new basement membrane and the entrapment of immune complexes, complement factors, cellular elements, and matrix material, resulting in double contours along the capillary walls. Yellow oval structures indicate complement factors. The term sMAC denotes soluble membrane-attack complex.

AUTOIMMUNE DISEASES

MPGN occurs in a number of autoimmune diseases. These include systemic lupus erythematosus and, occasionally, Sjögren's syndrome, rheumatoid arthritis, and mixed connective-tissue disorders.[31-35]

MONOCLONAL GAMMOPATHY

Recent studies indicate that glomerular deposition of monoclonal immunoglobulin as a result of monoclonal gammopathy (also called dysproteinemia or plasma-cell dyscrasia), with or without cryoglobulins, is associated with MPGN.[36-39] Monoclonal gammopathy is characterized by the proliferation of a single clone of immunoglobulin-producing lymphocytes or plasma cells, resulting in the circulation of monoclonal immunoglobulin. In one single-center study, 41% of the patients who had MPGN without an autoimmune process or chronic infection had evidence of monoclonal gammopathy, as assessed by means of serum electrophoresis, urine electrophoresis, or both.[36]

The New England Journal of Medicine
Downloaded from nejm.org by LUIGI GRECO on April 16, 2012. For personal use only. No other uses without permission.
Copyright © 2012 Massachusetts Medical Society. All rights reserved.

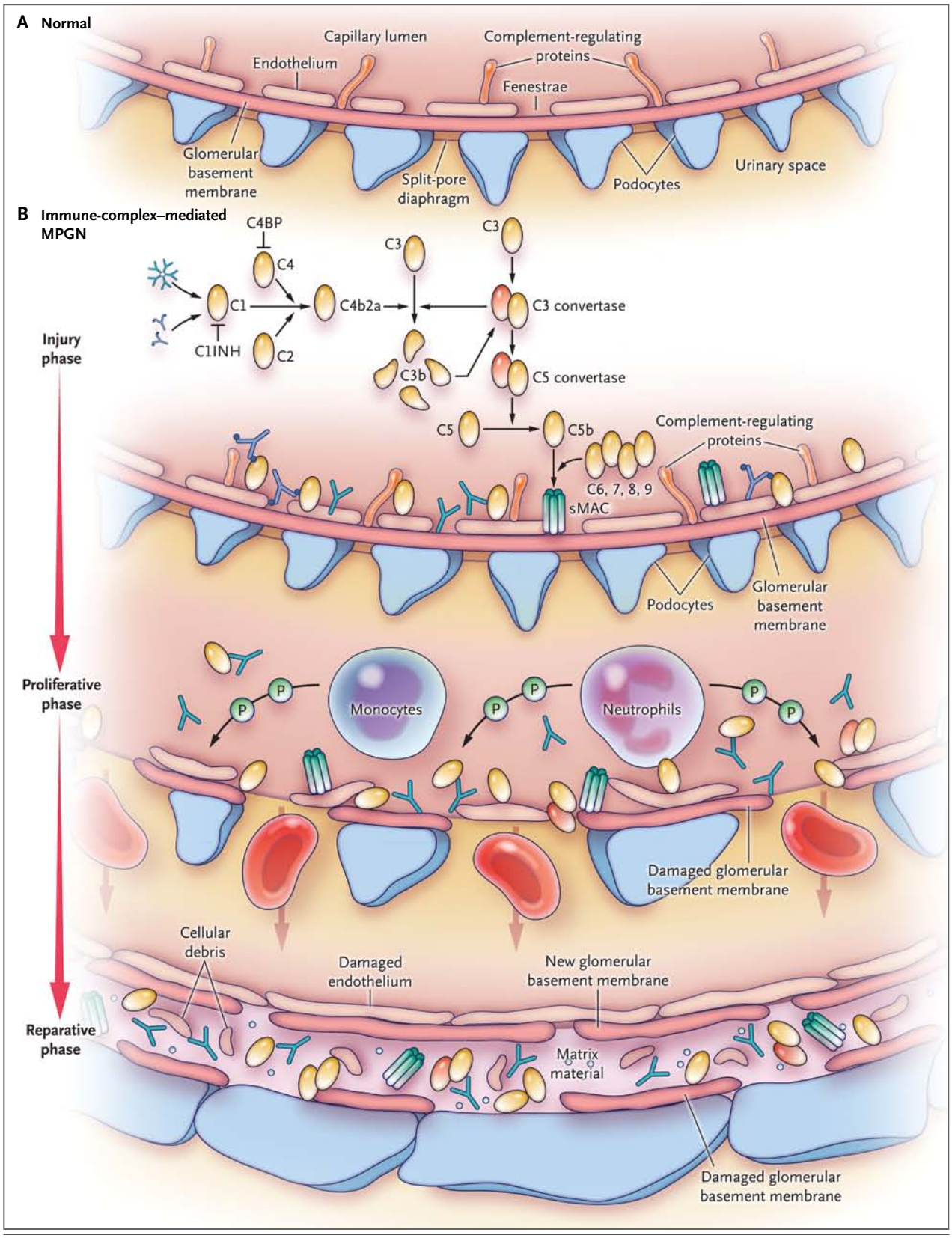

The New England Journal of Medicine
Downloaded from nejm.org by LUIGI GRECO on April 16, 2012. For personal use only. No other uses without permission.
Copyright © 2012 Massachusetts Medical Society. All rights reserved.

Bone marrow biopsies on such patients revealed a variety of conditions: monoclonal gammopathy of undetermined significance (MGUS) (the most common condition), low-grade B-cell lymphoma, lymphoplasmacytic lymphoma, chronic lymphocytic leukemia, and multiple myeloma. The authors suggested that patients with monoclonal gammopathy and MPGN should be classified as having "monoclonal gammopathy–associated MPGN" rather than MGUS.[36]

COMPLEMENT-MEDIATED MPGN

The complement cascade plays an important role in innate immunity. Complement factors can induce a potent inflammatory response that results in phagocyte chemotaxis, with opsonization and lysis of cells, including microorganisms. Complement activation occurs through the classical, lectin, or alternative pathways, all of which converge to form C3 convertase, which cleaves C3 into C3a and C3b. C3b, in the presence of factor B and factor D, associates with C3 convertase, generating even more C3 convertase and resulting in a potent amplification loop (Fig. 2, and Fig. 1 in the Supplementary Appendix). Thus, C3 convertase is a nodal point in the complement cascade. The association of C3b and C3 convertase also results in the formation of C5 convertase, which activates the terminal complement complex pathway and the formation of the membrane-attack complex (C5b–C9) on cell surfaces, thereby resulting in cell lysis.[40,41]

The alternative pathway is continually active at low levels in the circulation (fluid phase) through spontaneous hydrolysis of the thioester bond of C3 ("tick over" mechanism), which generates C3b; C3b then binds to host cell membranes and extracellular membranes such as the glomerular basement membrane (surface phase) as well as membranes of pathogenic microorganisms.[42,43] To prevent self-damage, activation of the alternative pathway occurs in a tightly regulated, sequential manner. Multiple complement-regulating and complement-inhibiting proteins operate at different levels of the cascade, particularly at the C3 and C5 convertase level.[41] Such plasma or fluid-phase regulators include factors H and I and factor H–related proteins 1 through 5 and cell-bound and surface regulators such as decay-accelerating factor (CD55), complement receptor 1, CD59, membrane cofactor protein (CD46), and complement receptor of the immunoglobulin superfamily.[40-42] Factor H accelerates the breakdown of C3 convertase and is a cofactor for factor I–mediated cleavage and inactivation of C3b,[41,42] thereby controlling the alternative pathway in the fluid phase. Fluid-phase regulators of the terminal complement complex include vitronectin and clusterin. Some of the fluid-phase regulators, including factor H and factor H–related protein 1, also attach to cell surfaces and extracellular membranes, adding an extra protective mechanism to prevent the formation of active complement products.[41] Surface regulators control C3 convertase through the inactivation of C3b deposited on cell surfaces and basement membranes.[44]

Dysregulation of the alternative pathway can occur because of mutations in or autoantibodies to complement-regulating proteins (Fig. 3). For example, mutations in proteins that regulate the assembly and activity of C3 convertase and degradation of C3b, such as factors H, I, and B and factor H–related protein 5, result in dysregulation of the alternative pathway.[45-53] Heterozygous mutations in C3 itself cause fluid-phase dysregulation of the alternative pathway, because the mutant C3 is resistant to cleavage by C3 convertase. In addition, the generation through the tick-over mechanism of an abnormal C3 convertase, which contains the C3 mutation, renders it resistant to inactivation by factor H. The abnormal C3 convertase then cleaves C3 produced by the normal C3 allele, resulting in increased levels of C3 breakdown products.[54] Similarly, antibodies to the complement-regulating proteins (such as factors H and B) and to C3 convertase itself can result in overactivity of the alternative pathway.[49,55] Antibodies to C3 convertase (called C3 nephritic factor) stabilize the convertase and prolong its half-life by preventing its inactivation and degradation, thereby activating the alternative pathway.[40,45]

Certain genetic polymorphisms in factors H and B, membrane cofactor protein, and C3 are also associated with MPGN.[56,57] Polymorphisms in the gene encoding factor H, notably Tyr402His allele variants, are the polymorphisms that have been studied most often. As compared with Tyr402, His402 is overrepresented in patients with MPGN and alternative-pathway abnormalities, and functional studies show that His402 impairs factor H–mediated regulation of C3 convertase on cell surfaces.[49,58,59]

Whatever the mechanism may be, dysregulation of the alternative pathway results in activated

The New England Journal of Medicine
Downloaded from nejm.org by LUIGI GRECO on April 16, 2012. For personal use only. No other uses without permission.
Copyright © 2012 Massachusetts Medical Society. All rights reserved.

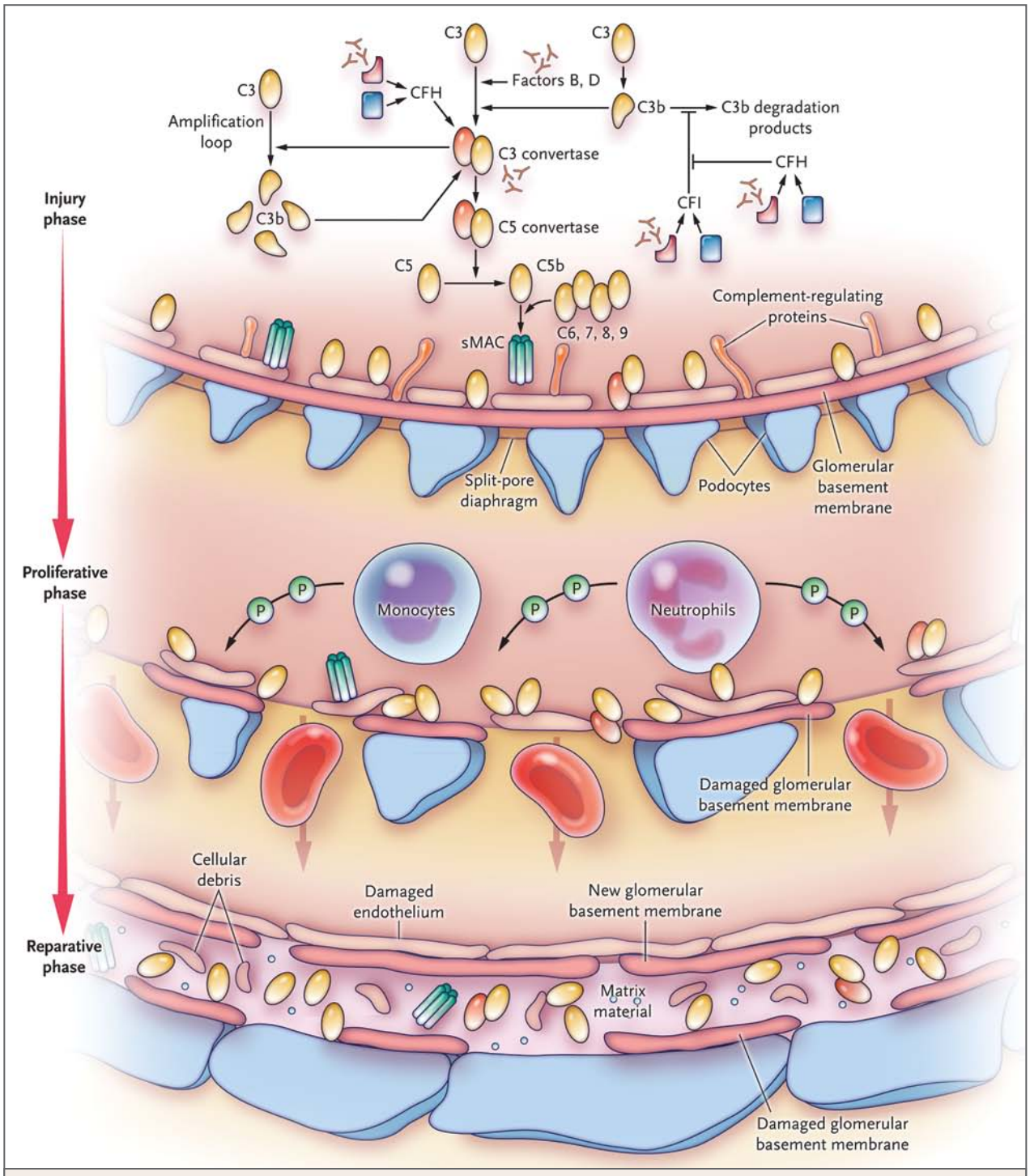

Figure 2. Complement-Mediated MPGN.

A schematic model of MPGN associated with dysregulation of the alternative pathway is shown. The injury phase develops because of the deposition of complement factors of the alternative pathway and terminal complement complex due to mutations and antibodies to complement-regulating proteins. Antibodies (Y-shaped pink structures) are shown against complement factor H (CFH), factor I (CFI), factor B, and C3 convertase (C3 nephritic factor). The proliferative and reparative phases are as described for immune-complex–mediated MPGN in Figure 1. Red notched boxes indicate mutations, and blue boxes allele variants.

The New England Journal of Medicine
Downloaded from nejm.org by LUIGI GRECO on April 16, 2012. For personal use only. No other uses without permission.
Copyright © 2012 Massachusetts Medical Society. All rights reserved.

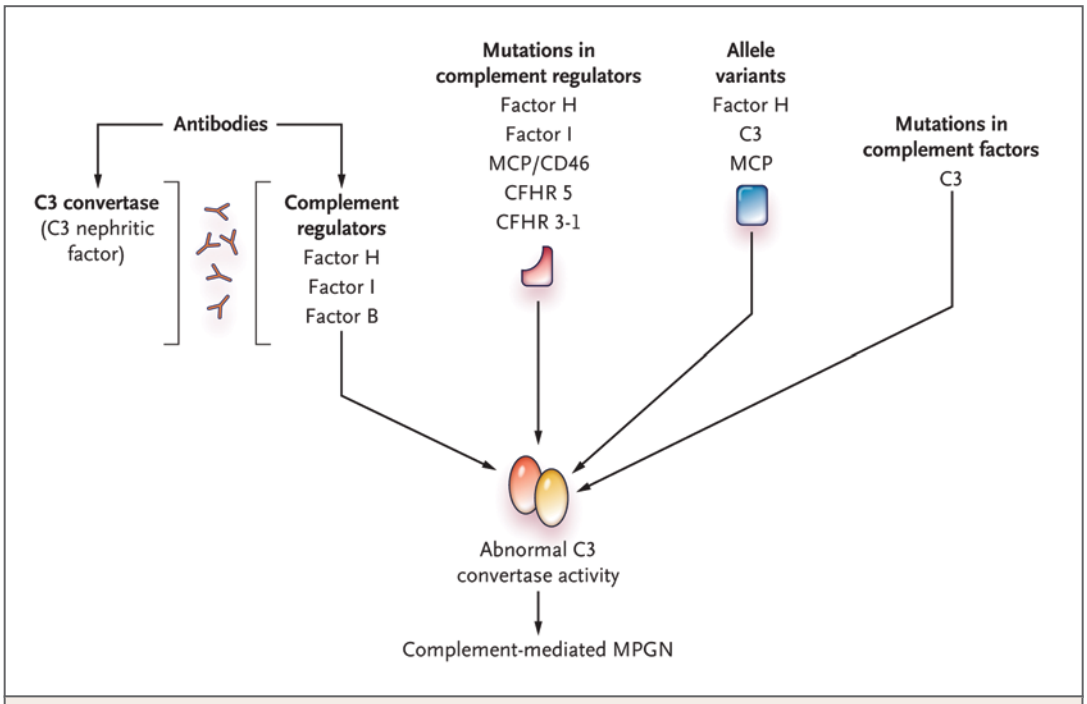

Figure 3. Acquired and Genetic Abnormalities Associated with Complement-Mediated MPGN.
Acquired abnormalities include antibodies to complement-regulating proteins, such as antibodies to C3 convertase (C3 nephritic factor). Genetic abnormalities include mutations in the complement (represented by the notched red box) and in complement-regulating proteins, including allele variants (blue box). CFHR denotes complement factor H–related proteins, and MCP membrane cofactor protein.

complement products, including C3b and terminal complement factors, which are delivered indiscriminately to endothelial surfaces, including glomeruli.[41,60] The deposition of these complement products and debris in the mesangium and subendothelial region triggers glomerular inflammation and leads to MPGN. Immunoglobulins are not directly involved; thus, complement-mediated MPGN is typically immunoglobulin-negative but complement-positive on immunofluorescence studies.

Despite multiple genetic risk factors, MPGN due to complement abnormalities often develops relatively late in life, suggesting that additional insults or environmental factors are required. Furthermore, MPGN does not develop in all genetically similar members of high-risk families, again indicating that additional disease-inducing factors are required. We speculate that when MPGN does not occur despite the presence of a mutation or of an allele variant that confers a predisposition to the disease, redundant control mechanisms may be present.[43] However, when an additional insult such as a complement-activating infection occurs, it may overwhelm the compensatory regulatory mechanism, triggering glomerular deposition of complement factors.[41] This scenario may explain the recurrent episodes of macroscopic hematuria associated with infections (synpharyngitic hematuria) that are noted in many patients with MPGN. Similarly, an additional insult, such as the production of monoclonal proteins that act as autoantibodies to complement-regulating proteins in patients with MGUS, could result in dysregulation of the alternative pathway and the development of MPGN.[61,62]

PATHOLOGICAL FEATURES

The deposition of immunoglobulin, complement, or both in the mesangium and subendothelial region of the capillary wall triggers an acute injury, which is often followed by an inflammatory (cellular or proliferative) phase, with an influx of inflammatory cells. A subsequent reparative phase occurs, during which new mesangial matrix results in mesangial expansion, along with the generation of

The New England Journal of Medicine
Downloaded from nejm.org by LUIGI GRECO on April 16, 2012. For personal use only. No other uses without permission.
Copyright © 2012 Massachusetts Medical Society. All rights reserved.

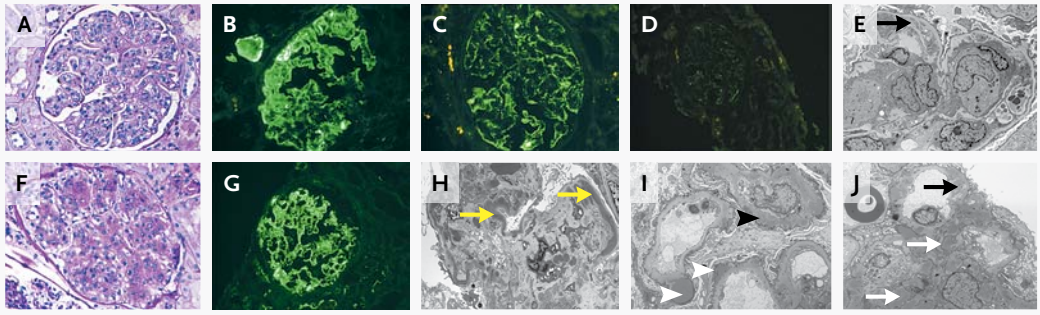

Figure 4. Representative Findings on Light, Immunofluorescence, and Electron Microscopy in MPGN.
Panels A through E show MPGN associated with monoclonal gammopathy. Light microscopy shows an MPGN pattern of injury (Panel A). Immunofluorescence microscopy shows positive staining for IgM (Panel B) and kappa light chains (Panel C) and negative staining for lambda light chains (Panel D), indicating monotypic IgM kappa deposition. Electron microscopy shows subendothelial deposits (arrow in Panel E) and double-contour formation. Panels F through J show MPGN due to dysregulation of the alternative pathway of complement. Light microscopy shows an MPGN pattern of injury (Panel F). Immunofluorescence microscopy shows bright C3 staining (Panel G). Immunoglobulin, C1q, kappa, and lambda staining are negative. Electron microscopy shows dense osmiophilic deposits (arrows in Panel H) along the glomerular basement membranes in dense-deposit disease and mesangial, subendothelial, intramembranous, and subepithelial deposits and double contours in C3 glomerulonephritis (Panels I and J). Black arrows indicate subendothelial deposits, white arrows mesangial deposits, white arrowheads subepithelial deposits, and the black arrowhead intramembranous deposits.

new glomerular basement membrane, which looks like a duplicated basement membrane (so-called tram tracks or double contours) (Fig. 1 and 2).

Immunofluorescence findings are used to distinguish immune-complex–mediated MPGN from complement-mediated MPGN and can often point to a specific cause. For example, MPGN associated with monoclonal gammopathy shows monotypic immunoglobulin with kappa or lambda light-chain restriction (Fig. 4). MPGN associated with hepatitis C infection typically shows IgM, IgG, C3, and kappa and lambda light chains. An MPGN pattern in association with autoimmune diseases often includes multiple immunoglobulins and complement proteins — IgG, IgM, IgA, C1q, C3, and kappa and lambda light chains. MPGN associated with alternative-pathway dysfunction is characterized by bright C3 immunostaining in the mesangium and along the capillary walls (Fig. 4). The absence of marked immunoglobulin staining on immunofluorescence microscopy distinguishes MPGN due to alternative-pathway dysfunction from immune-complex–mediated MPGN.

Electron microscopy typically reveals mesangial and subendothelial deposits and, in some cases, intramembranous and subepithelial deposits. During the reparative phase, new basement membrane forms, entrapping capillary-wall deposits, along with cellular elements derived from inflammatory, mesangial, and endothelial cells, within the new basement-membrane material; the result is a thickening of the capillary walls and the formation of double contours along the capillary walls. With the exception of dense-deposit disease, electron microscopy cannot distinguish between immune-complex–mediated MPGN and complement-mediated MPGN.

MPGN due to alternative-pathway dysregulation may be subdivided into dense-deposit disease and C3 glomerulonephritis (C3GN), on the basis of electron-microscopical findings. Dense-deposit disease is characterized by osmiophilic, sausage-shaped, wavy, dense deposits that replace the glomerular basement membrane and also occur in the mesangium, whereas C3GN has mesangial, subendothelial, and sometimes subepithelial and intramembranous deposits (Fig. 4). On the basis of the morphologic characteristics of C3GN on electron microscopy, C3GN is most likely to be termed MPGN I or MPGN III according to the older classification. Data from laser microdissection and mass spectrometric analysis of glomeruli obtained from patients with C3GN are consistent with unrestricted activation of the alternative pathway, and the proteomic profile in such patients is similar to that in patients with dense-deposit dis-

The New England Journal of Medicine
Downloaded from nejm.org by LUIGI GRECO on April 16, 2012. For personal use only. No other uses without permission.
Copyright © 2012 Massachusetts Medical Society. All rights reserved.

ease.[49,60] The hypothesis that dense-deposit disease and C3GN are part of a continuum is further supported by cases that show features that are intermediate between dense-deposit disease and C3GN, with some capillary loops showing the sausage-shaped intramembranous deposits of dense-deposit disease and other loops showing the subendothelial and subepithelial deposits of C3GN on electron microscopy.

Five cases of immune-complex–mediated or complement-mediated MPGN with a clearly identifiable cause are discussed in the Supplementary Appendix.

ALTERNATIVE-PATHWAY DYSREGULATION AND DISEASE SUBTYPE

Dysregulation of the alternative pathway results in dense-deposit disease in some patients and C3GN in others, most likely because of differences in the degree or site (or both) of the dysregulation. In addition, certain allele variations of complement-regulating proteins may be associated with dense-deposit disease, and others may be associated with C3GN.[57]

OTHER PATTERNS OF IMMUNE-COMPLEX–MEDIATED AND COMPLEMENT-MEDIATED GLOMERULAR INJURY

Other patterns of glomerular injury besides MPGN may result from the deposition of immunoglobulin, complement, or both. For example, mesangial proliferative glomerulonephritis, diffuse proliferative glomerulonephritis, crescentic glomerulonephritis, and a sclerosing glomerulopathy can be present in both C3GN and dense-deposit disease.[63,64] The umbrella term "C3 glomerulopathy" describes the various patterns of injury,[65] which probably depend on multiple factors, including the severity of injury and the phase of the disease process (acute or chronic) at the time the biopsy is performed. Prior treatment may also affect the biopsy findings.

MPGN WITHOUT IMMUNE COMPLEXES OR COMPLEMENT

A pattern of injury consistent with MPGN is also noted in thrombotic microangiopathies resulting from injury to the endothelial cells. In the acute phase, mesangiolysis, endothelial swelling, and fibrin thrombi are present in the glomerular capillaries. As the process evolves into a reparative and chronic phase, mesangial expansion and remodeling of the glomerular capillary walls, including double-contour formation, take place. Thus, the healing phase of thrombotic thrombocytopenic purpura or hemolytic–uremic syndrome, atypical hemolytic–uremic syndrome associated with complement abnormalities, the antiphospholipid antibody syndrome, drug-induced thrombotic microangiopathies, nephropathy associated with bone marrow transplantation, radiation nephritis, malignant hypertension, and connective-tissue disorders can all present with an MPGN pattern of injury on biopsy.[66,67] In thrombotic microangiopathies, immunoglobulin and complement are typically absent on immunofluorescence, and electron-dense deposits are not present in the mesangium or along the capillary walls on electron microscopy.

EVALUATION

Persistently decreased serum levels of complement C3, C4, or both are commonly seen in patients with MPGN. Low C3 and low C4 complement levels are more common in immune-complex–mediated MPGN, whereas low C3 and normal C4 levels are more common in alternative-pathway dysfunction, particularly in the acute phase. A normal C3 level does not rule out alternative-pathway dysfunction.

When a kidney-biopsy specimen from a patient with MPGN shows immunoglobulins, an evaluation for infections, autoimmune diseases, and monoclonal gammopathies is indicated (Fig. 5). Relevant tests for the detection of infections include blood cultures and polymerase-chain-reaction and serologic tests for viral, bacterial, and fungal infections. Cryoglobulins may be present. Tests for the detection of monoclonal gammopathy include serum and urine electrophoresis, immunofixation studies, and free light-chain assays; positive results necessitate bone marrow studies for a more precise diagnosis. Positive screening tests for an autoimmune disease should be followed by specific tests for the autoimmune disease.

If the biopsy specimen from a patient with MPGN shows bright C3 immunostaining (with minimal or no immunoglobulin staining), an evaluation to detect abnormalities of the alternative pathway is indicated regardless of whether an electron microscopic examination shows dense-deposit disease or C3GN (Fig. 5). The initial evaluation of the alternative pathway should include measurement of serum complement levels and serum levels of the membrane-attack complex, an alternative pathway functional assay, and

The New England Journal of Medicine
Downloaded from nejm.org by LUIGI GRECO on April 16, 2012. For personal use only. No other uses without permission.
Copyright © 2012 Massachusetts Medical Society. All rights reserved.

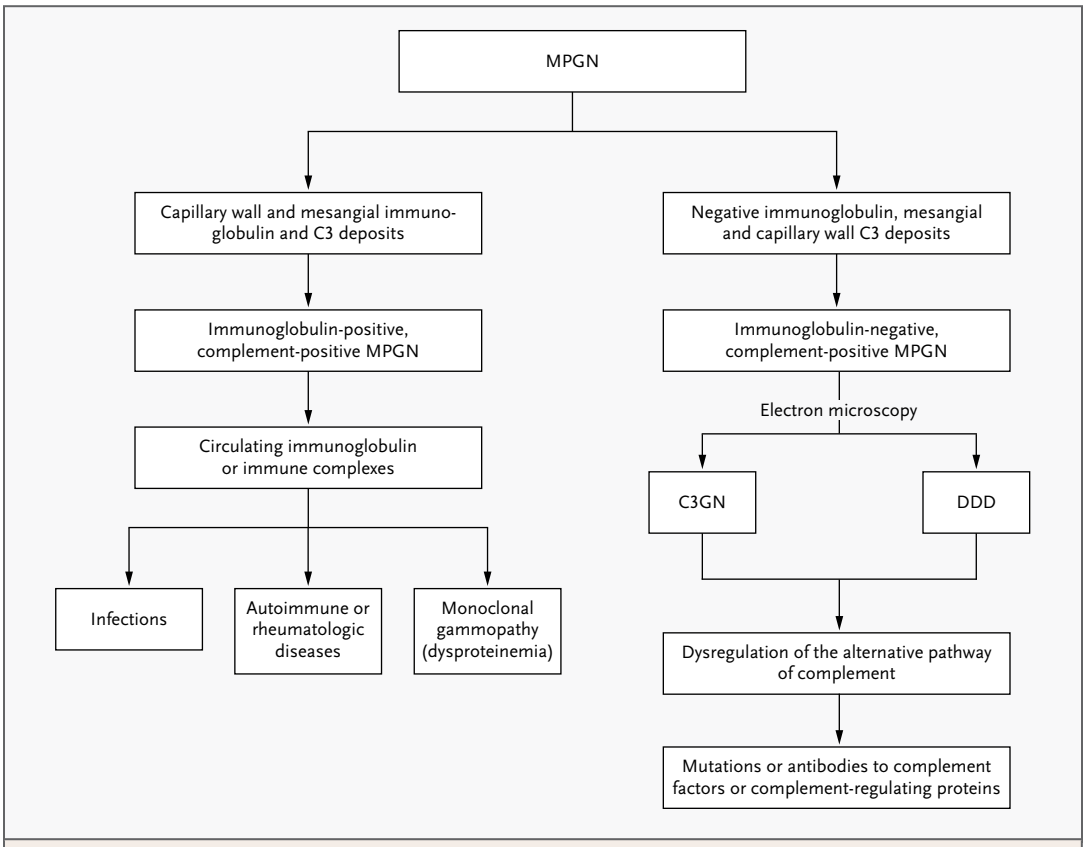

Figure 5. Pathophysiology of MPGN.

On the basis of the immunofluorescence findings, MPGN can be broadly divided into immunoglobulin-positive, complement-positive MPGN and immunoglobulin-negative, complement-positive MPGN. The presence of immunoglobulin-positive, complement-positive MPGN necessitates evaluation for infections, autoimmune diseases, and monoclonal gammopathies. Immunoglobulin-negative, complement-positive MPGN is further divided into dense-deposit disease (DDD) and C3 glomerulonephritis (C3GN), depending on the electron-microscopical findings; its presence necessitates evaluation of the alternative pathway of complement.

hemolytic complement assays, followed by genetic analysis for mutations and allele variants of complement factors and assays for the presence of autoantibodies to complement-regulating proteins, including tests for the detection of C3 nephritic factor (Fig. 7 in the Supplementary Appendix).

Even after extensive evaluation, the cause may remain enigmatic in a few cases of immune-complex–mediated or complement-mediated MPGN. In some patients, immune-complex–mediated MPGN may be initiated by immunoglobulin deposition, but the disease may be accelerated by alternative-pathway abnormalities.[68] Over time, new methods will probably be developed that can further separate specific causes of MPGN from idiopathic cases.

THERAPY

Early reports on the treatment of "idiopathic" MPGN should be interpreted with caution. In many instances, historical controls were used, the statistical significance was marginal, or the power to detect substantial differences was small.[69,70] Most early studies antedated the use of angiotensin-converting–enzyme (ACE) inhibitors and angiotensin II–receptor blockers, and the protean pathogenic processes that lead to MPGN were as yet unknown. Thus, most studies on MPGN conflated various types of MPGN in unknown proportions.[71]

The benefit of long-term alternate-day glucocorticoid therapy for idiopathic MPGN in children was suggested by a few uncontrolled studies[72-74] and one randomized, controlled trial.[75] However,

The New England Journal of Medicine
Downloaded from nejm.org by LUIGI GRECO on April 16, 2012. For personal use only. No other uses without permission.
Copyright © 2012 Massachusetts Medical Society. All rights reserved.

these studies included a mix of patients with MPGN I, MPGN III, and dense-deposit disease, limiting the conclusions that could be reached. There has been no systematic evaluation of glucocorticoid therapy for idiopathic MPGN in adults. Retrospective studies showed no clear benefit from glucocorticoid therapy, but treatment was not as prolonged in adults as it was in children.[70,76]

Early claims of the beneficial effects of anticoagulants (i.e., heparin and warfarin), frequently combined with glucocorticoids and cytotoxic agents, have not been confirmed in a prospective study.[77] Similarly, an early randomized, controlled trial showed that the combination of aspirin and dipyridamole slowed the decline in the glomerular filtration rate in adults with idiopathic MPGN,[78] but there was no long-term benefit, suggesting that prolonged antiplatelet therapy is required for a sustained benefit.[70] Limited uncontrolled data suggest that calcineurin inhibitors may reduce proteinuria in some patients with MPGN.[79-82] In patients with a rapidly progressive course and crescents on renal biopsy, a few small, uncontrolled studies have suggested a benefit with high-dose "pulse" glucocorticoids, either as monotherapy[83-85] or in combination with azathioprine,[86] cyclophosphamide,[87] or mycophenolate mofetil.[88-90]

The lack of randomized, controlled trials and the current understanding that multiple pathogenic processes lead to MPGN make it impossible to give strong treatment recommendations in this patient population. Pragmatic considerations would suggest that patients with MPGN due to chronic infections should undergo treatment of the infection, and those with MPGN due to an autoimmune disease should undergo treatment of the autoimmune disease. Similarly, patients with MPGN due to a monoclonal gammopathy should undergo treatment aimed at attaining remission of the hematologic dyscrasia. A recent study involving patients with MPGN associated with monoclonal immunoglobulin deposits and no overt hematologic cancer showed that patients had a good response to rituximab.[91] Patients with normal kidney function, no active urinary sediment, and non–nephrotic-range proteinuria can be treated conservatively with angiotensin II blockade to control blood pressure and reduce proteinuria, since the long-term outcome is relatively benign in this context.[92,93] Follow-up is required to detect early deterioration in kidney function.

A better understanding of the causes and pathogenesis of complement-mediated MPGN would logically set the stage for the possible use of newer drugs, including anticomplement drugs. However, current recommendations are based on theory, not studies. For example, patients with MPGN due to autoantibodies to complement-regulating proteins may benefit from immunosuppressive therapy (e.g., glucocorticoids and rituximab), whereas those with MPGN due to a genetic mutation in complement-regulating proteins may benefit from treatment with drugs that inhibit formation of the membrane-attack complex (e.g., eculizumab).

Eculizumab, an anti-C5 monoclonal antibody that inhibits C5 activation, has been used successfully in patients with atypical hemolytic–uremic syndrome due to complement abnormalities in the alternative pathway.[94-96] The role of such anticomplement agents in MPGN is not delineated but offers exciting possibilities for the future. It is also conceivable that patients with elevated serum levels of the membrane-attack complex may be more likely than those with normal levels to have a response to treatment with eculizumab. Patients with MPGN due to a deficiency of factor H might benefit from plasma infusion[97] or infusion of factor H. Patients who present with advanced renal insufficiency and severe tubulointerstitial fibrosis on renal biopsy are unlikely to benefit from immunosuppressive therapy.

RECURRENCE AFTER KIDNEY TRANSPLANTATION

MPGN often recurs in kidney-transplant recipients. Recurrence rates range from 27 to 65%, depending on the study.[98-100] One recent study, which excluded from the analysis patients with dense-deposit disease, showed a recurrence rate of 41%; of patients with a recurrence, 36% had a monoclonal gammopathy. The study showed that recurrent MPGN due to deposition of monoclonal immunoglobulin was associated with early recurrence and a more aggressive course.[100] Low complement levels were shown to be an early marker for recurrent MPGN.[100] Few data exist on the recurrence of C3GN. In patients with dense-deposit disease, there is almost universal recurrence of disease, with a 5-year rate of allograft failure of 50%.[40,45]

The New England Journal of Medicine
Downloaded from nejm.org by LUIGI GRECO on April 16, 2012. For personal use only. No other uses without permission.
Copyright © 2012 Massachusetts Medical Society. All rights reserved.

CONCLUSIONS

Two major pathophysiological factors — the deposition of immunoglobulin and the deposition of complement in the glomerular mesangium and capillary walls — may lead to MPGN. The presence of immune-complex–mediated MPGN necessitates evaluation for infections, autoimmune diseases, and monoclonal gammopathy. Complement-mediated MPGN is further subdivided into dense-deposit disease and C3GN, depending on the electron-microscopical findings; the presence of complement-mediated MPGN necessitates evaluation of the alternative pathway. Evaluation of MPGN according to the underlying pathophysiological processes may facilitate proper treatment.

No potential conflict of interest relevant to this article was reported.

Disclosure forms provided by the authors are available with the full text of this article at NEJM.org.

We thank Dr. An De Vriese for helpful comments on an earlier version of the manuscript.

REFERENCES

1. Swaminathan S, Leung N, Lager DJ, et al. Changing incidence of glomerular disease in Olmsted County, Minnesota: a 30-year renal biopsy study. Clin J Am Soc Nephrol 2006;1:483-7.

2. Briganti EM, Dowling J, Finlay M, et al. The incidence of biopsy-proven glomerulonephritis in Australia. Nephrol Dial Transplant 2001;16:1364-7.

3. Braden GL, Mulhern JG, O'Shea MH, Nash SV, Ucci AA Jr, Germain MJ. Changing incidence of glomerular diseases in adults. Am J Kidney Dis 2000;35:878-83.

4. Zhou FD, Zhao MH, Zou WZ, Liu G, Wang H. The changing spectrum of primary glomerular diseases within 15 years: a survey of 3331 patients in a single Chinese centre. Nephrol Dial Transplant 2009; 24:870-6.

5. Maisonneuve P, Agodoa L, Gellert R, et al. Distribution of primary renal diseases leading to end-stage renal failure in the United States, Europe, and Australia/New Zealand: results from an international comparative study. Am J Kidney Dis 2000;35:157-65.

6. Jennette JC, Olson LJ, Schwartz MM, Silva GF, eds. Heptinstall's pathology of the kidney. 6th ed. Philadelphia: Lippincott Williams & Wilkins, 2007.

7. Kumar V, Abul AK, Fausto N, Aster J, eds. Pathologic basis of disease. 8th ed. Philadelphia: Elsevier Saunders, 2010.

8. Rennke HG. Secondary membranoproliferative glomerulonephritis. Kidney Int 1995;47:643-56.

9. Sethi S, Fervenza FC. Membranoproliferative glomerulonephritis: pathogenetic heterogeneity and proposal for a new classification. Semin Nephrol 2011;31: 341-8.

10. Doutrelepont J-M, Adler M, Willems M, Durez P, Yap S-H. Hepatitis C infection and membranoproliferative glomerulonephritis. Lancet 1993;341:317.

11. Johnson RJ, Gretch DR, Yamabe H, et al. Membranoproliferative glomerulonephritis associated with hepatitis C virus infection. N Engl J Med 1993;328:465-70.

12. Roccatello D, Fornasieri A, Giachino O, et al. Multicenter study on hepatitis C virus-related cryoglobulinemic glomerulonephritis. Am J Kidney Dis 2007;49:69-82.

13. Smith KD, Alpers CE. Pathogenic mechanisms in membranoproliferative glomerulonephritis. Curr Opin Nephrol Hypertens 2005;14:396-403.

14. Rincón B, Bernis C, Arcia A, Traver JA. Mesangiocapillary glomerulonephritis associated with hydatid disease. Nephrol Dial Transplant 1993;8:783-4.

15. Martinelli R, Noblat AC, Brito E, Rocha H. Schistosoma mansoni-induced mesangiocapillary glomerulonephritis: influence of therapy. Kidney Int 1989;35:1227-33.

16. Rodrigues VL, Otoni A, Voieta I, Antunes CM, Lambertucci JR. Glomerulonephritis in Schistosomiasis mansoni: a time to reappraise. Rev Soc Bras Med Trop 2010;43:638-42.

17. Ohara S, Kawasaki Y, Takano K, et al. Glomerulonephritis associated with chronic infection from long-term central venous catheterization. Pediatr Nephrol 2006;21:427-9.

18. Vella J, Carmody M, Campbell E, Browne O, Doyle G, Donohoe J. Glomerulonephritis after ventriculo-atrial shunt. QJM 1995;88:911-8.

19. Kai H, Shimizu Y, Hagiwara M, et al. Post-MRSA infection glomerulonephritis with marked Staphylococcus aureus cell envelope antigen deposition in glomeruli. J Nephrol 2006;19:215-9.

20. Ades L, Akposso K, Costa de Beauregard MA, et al. Bacterial endocarditis associated with crescentic glomerulonephritis in a kidney transplant patient: first case report. Transplantation 1998;66:653-4.

21. Pecchini F, Bufano G, Ghiringhelli P. Membranoproliferative glomerulonephritis secondary to tuberculosis. Clin Nephrol 1997;47:63-4.

22. Bonarek H, Bonnet F, Delclaux C, Deminière C, De Précigout V, Aparicio M. Reversal of c-ANCA positive mesangiocapillary glomerulonephritis after removal of an infected cysto-atrial shunt. Nephrol Dial Transplant 1999;14:1771-3.

23. Laso MC, Cadario M, Haymes L, Grimoldi I, Balbarrey Z, Casanueva E. Mycoplasma pneumoniae detection with PCR in renal tissue of a patient with acute glomerulonephritis. Pediatr Nephrol 2006; 21:1483-6.

24. Altiparmak MR, Pamuk G, Pamuk O, Tabak F. Brucella glomerulonephritis: review of the literature and report on the first patient with brucellosis and mesangiocapillary glomerulonephritis. Scand J Infect Dis 2002;34:477-80.

25. Dathan JR, Heyworth MF. Glomerulonephritis associated with Coxiella burnetii endocarditis. BMJ 1975;1:376-7.

26. Jose MD, Bannister KM, Clarkson AR, Whitehead FJ, Faull RJ. Mesangiocapillary glomerulonephritis in a patient with Nocardia pneumonia. Nephrol Dial Transplant 1998;13:2628-9.

27. Elmaci I, Senday D, Silav G, et al. Nocardial cerebral abscess associated with mycetoma, pneumonia, and membranoproliferative glomerulonephritis. J Clin Microbiol 2007;45:2072-4.

28. Hulton SA, Risdon RA, Dillon MJ. Mesangiocapillary glomerulonephritis associated with meningococcal meningitis, C3 nephritic factor and persistently low complement C3 and C5. Pediatr Nephrol 1992;6:239-43.

29. Boseman P, Lewin M, Dillon J, Sethi S. Marfan syndrome, MPGN, and bacterial endocarditis. Am J Kidney Dis 2008; 51:697-701.

30. Haffner D, Schindera F, Aschoff A, Matthias S, Waldherr R, Schärer K. The clinical spectrum of shunt nephritis. Nephrol Dial Transplant 1997;12:1143-8.

31. Weening JJ, D'Agati VD, Schwartz MM, et al. The classification of glomerulonephritis in systemic lupus erythematosus revisited. J Am Soc Nephrol 2004;15: 241-50. [Erratum, Am J Soc Nephrol 2004; 15:835-6.]

32. Goules A, Masouridi S, Tzioufas AG, Ioannidis JPA, Skopouli FN, Moutsopoulos HM. Clinically significant and biopsy-documented renal involvement in primary Sjögren syndrome. Medicine 2000;79: 241-9.

The New England Journal of Medicine
Downloaded from nejm.org by LUIGI GRECO on April 16, 2012. For personal use only. No other uses without permission.
Copyright © 2012 Massachusetts Medical Society. All rights reserved.

33. Cortez MS, Sturgill BC, Bolton WK. Membranoproliferative glomerulonephritis with primary Sjögren's syndrome. Am J Kidney Dis 1995;25:632-6.
34. Suzuki H, Hickling P, Lyons CB. A case of primary Sjögren's syndrome, complicated by cryoglobulinemic glomerulonephritis, pericardial and pleural effusions. Br J Rheumatol 1996;35:72-5.
35. Ting HC, Wang F. Mesangiocapillary (membranoproliferative) glomerulonephritis and rheumatoid arthritis. BMJ 1977;1:270-1.
36. Sethi S, Zand L, Leung N, et al. Membranoproliferative glomerulonephritis secondary to monoclonal gammopathy. Clin J Am Soc Nephrol 2010;5:770-82.
37. Salant DJ, Sanchorawala V, D'Agati VD. A case of atypical light chain deposition disease — diagnosis and treatment. Clin J Am Soc Nephrol 2007;2:858-67.
38. Vilayur E, Trevillian P, Walsh M. Monoclonal gammopathy and glomerulopathy associated with chronic lymphocytic leukemia. Nat Clin Pract Nephrol 2009;5:54-8.
39. Nasr SH, Satoskar A, Markowitz GS, et al. Proliferative glomerulonephritis with monoclonal IgG deposits. J Am Soc Nephrol 2009;20:2055-64.
40. Smith RJH, Alexander J, Barlow PN, et al. New approaches to the treatment of dense deposit disease. J Am Soc Nephrol 2007;18:2447-56.
41. Zipfel PF, Skerka C. Complement regulators and inhibitory proteins. Nat Rev Immunol 2009;9:729-40.
42. Ferreira VP, Pangburn MK, Cortés C. Complement control protein factor H: the good, the bad, and the inadequate. Mol Immunol 2010;47:2187-97.
43. Pangburn MK, Müller-Eberhard HJ. Initiation of the alternative complement pathway due to spontaneous hydrolysis of the thioester of C3a. Ann N Y Acad Sci 1983;421:291-8.
44. Zipfel PF, Smith RJH, Skerka C. Factor I and factor H deficiency in renal diseases: similar defects in the fluid phase have a different outcome at the surface of the glomerular basement membrane. Nephrol Dial Transplant 2009;24:385-7.
45. Appel GB, Cook HT, Hageman G, et al. Membranoproliferative glomerulonephritis type II (dense deposit disease): an update. J Am Soc Nephrol 2005;16:1392-403.
46. Habbig S, Mihatsch MJ, Heinen S, et al. C3 deposition glomerulopathy due to a functional factor H defect. Kidney Int 2009;75:1230-4.
47. Servais A, Frémeaux-Bacchi V, Lequintrec M, et al. Primary glomerulonephritis with isolated C3 deposits: a new entity which shares common genetic risk factors with haemolytic uraemic syndrome. J Med Genet 2007;44:193-9.
48. Gale DP, de Jorge EG, Cook HT, et al. Identification of a mutation in complement factor H-related protein 5 in patients of Cypriot origin with glomerulonephritis. Lancet 2010;376:794-801.
49. Sethi S, Fervenza FC, Zhang Y, et al. Proliferative glomerulonephritis secondary to dysfunction of the alternative pathway of complement. Clin J Am Soc Nephrol 2011;6:1009-17.
50. Józsi M, Zipfel PF. Factor H family proteins and human diseases. Trends Immunol 2008;29:380-7.
51. Athanasiou Y, Voskarides K, Gale DP, et al. Familial C3 glomerulopathy associated with CFHR5 mutations: clinical characteristics of 91 patients in 16 pedigrees. Clin J Am Soc Nephrol 2011;6:1436-46.
52. Licht C, Heinen S, Jozsi M, et al. Deletion of Lys224 in regulatory domain 4 of Factor H reveals a novel pathomechanism for dense deposit disease (MPGN II). Kidney Int 2006;70:42-50.
53. Zhang Y, Meyer NC, Wang K, et al. Causes of alternative pathway dysregulation in dense deposit disease. Clin J Am Soc Nephrol 2012;7:265-74.
54. Martínez-Barricarte R, Heurich M, Valdes-Cañedo F, et al. Human C3 mutation reveals a mechanism of dense deposit disease pathogenesis and provides insights into complement activation and regulation. J Clin Invest 2010;120:3702-12.
55. Strobel S, Zimmering M, Papp K, Prechl J, Józsi M. Anti-factor B autoantibody in dense deposit disease. Mol Immunol 2010;47:1476-83.
56. Abrera-Abeleda MA, Nishimura C, Frees K, et al. Allelic variants of complement genes associated with dense deposit disease. J Am Soc Nephrol 2011;22:1551-9.
57. Heurich M, Martínez-Barricarte R, Francis NJ, et al. Common polymorphisms in C3, factor B, and factor H collaborate to determine systemic complement activity and disease risk. Proc Natl Acad Sci U S A 2011;108:8761-6.
58. Abrera-Abeleda MA, Nishimura C, Smith JLH, et al. Variations in the complement regulatory genes factor H (CFH) and factor H related 5 (CFHR5) are associated with membranoproliferative glomerulonephritis type II (dense deposit disease). J Med Genet 2006;43:582-9.
59. Lau KK, Smith RJ, Kolbeck PC, Butani L. Dense deposit disease and the factor H H402 allele. Clin Exp Nephrol 2008;12:228-32.
60. Sethi S, Gamez JD, Vrana JA, et al. Glomeruli of dense deposit disease contain components of the alternative and terminal complement pathway. Kidney Int 2009;75:952-60.
61. Sethi S, Sukov WR, Zhang Y, et al. Dense deposit disease associated with monoclonal gammopathy of undetermined significance. Am J Kidney Dis 2010;56:977-82.
62. Bridoux F, Desport E, Frémeaux-Bacchi V, et al. Glomerulonephritis with isolated C3 deposits and monoclonal gammopathy: a fortuitous association? Clin J Am Soc Nephrol 2011;6:2165-74.
63. Servais A, Noël L-H, Dragon-Durey M-A, et al. Heterogeneous pattern of renal disease associated with homozygous Factor H deficiency. Hum Pathol 2011;42:1305-11.
64. Walker PD, Ferrario F, Joh K, Bonsib SM. Dense deposit disease is not a membranoproliferative glomerulonephritis. Mod Pathol 2007;20:605-16.
65. Fakhouri F, Frémeaux-Bacchi V, Noël L-H, Cook HT, Pickering MC. C3 glomerulopathy: a new classification. Nat Rev Nephrol 2010;6:494-9.
66. Goldberg RJ, Nakagawa T, Johnson RJ, Thurman JM. The role of endothelial cell injury in thrombotic microangiopathy. Am J Kidney Dis 2010;56:1168-74.
67. Noris M, Remuzzi G. Atypical hemolytic–uremic syndrome. N Engl J Med 2009;361:1676-87.
68. Pickering M, Cook HT. Complement and glomerular disease: new insights. Curr Opin Nephrol Hypertens 2011;20:271-7.
69. Glassock RJ. Membranoproliferative glomerulonephritis. In: Ponticelli C, Glassock RJ, eds. Treatment of primary glomerulonephritis. 2nd ed. Oxford, England: Oxford University Press, 2009:375-98.
70. Donadio JV Jr, Offord KP. Reassessment of treatment results in membranoproliferative glomerulonephritis, with emphasis on life-table analysis. Am J Kidney Dis 1989;14:445-51.
71. Alchi B, Jayne D. Membranoproliferative glomerulonephritis. Pediatr Nephrol 2010;25:1409-18.
72. McEnery PT, McAdams AJ, West CD. The effect of prednisone in a high-dose, alternate-day regimen on the natural history of idiopathic membranoproliferative glomerulonephritis. Medicine (Baltimore) 1985;64:401-24.
73. McEnery PT. Membranoproliferative glomerulonephritis: the Cincinnati experience — cumulative renal survival from 1957 to 1989. J Pediatr 1990;116:S109-14.
74. Ford DM, Briscoe DM, Shanley PF, Lum GM. Childhood membranoproliferative glomerulonephritis type I: limited steroid therapy. Kidney Int 1992;41:1606-12.
75. Tarshish P, Bernstein J, Tobin JN, Edelmann CM Jr. Treatment of mesangiocapillary glomerulonephritis with alternate-day prednisone — a report of the International Study of Kidney Disease in Children. Pediatr Nephrol 1992;6:123-30.
76. Schena FP, Cameron JS. Treatment of proteinuric idiopathic glomerulonephritides in adults: a retrospective survey. Am J Med 1988;85:315-26.
77. Cattran DC, Cardella CJ, Roscoe JM, et al. Results of a controlled drug trial in membranoproliferative glomerulonephritis. Kidney Int 1985;27:436-41.

The New England Journal of Medicine
Downloaded from nejm.org by LUIGI GRECO on April 16, 2012. For personal use only. No other uses without permission.
Copyright © 2012 Massachusetts Medical Society. All rights reserved.

78. Donadio JV Jr, Anderson CF, Mitchell JC III, et al. Membranoproliferative glomerulonephritis: a prospective clinical trial of platelet-inhibitor therapy. N Engl J Med 1984;310:1421-6.
79. Cattran DC. Current status of cyclosporin A in the treatment of membranous, IgA and membranoproliferative glomerulonephritis. Clin Nephrol 1991; 35:Suppl 1:S43-S47.
80. Matsumoto H, Shibasaki T, Ohno I, et al. Effect of cyclosporin monotherapy on proteinuria in a patient with membranoproliferative glomerulonephritis. Nippon Jinzo Gakkai Shi 1995;37:258-62. (In Japanese.)
81. Haddad M, Lau K, Butani L. Remission of membranoproliferative glomerulonephritis type I with the use of tacrolimus. Pediatr Nephrol 2007;22:1787-91.
82. Bagheri N, Nemati E, Rahbar K, Nobakht A, Einollahi B, Taheri S. Cyclosporine in the treatment of membranoproliferative glomerulonephritis. Arch Iran Med 2008;11:26-9.
83. Emre S, Sirin A, Alpay H, et al. Pulse methylprednisolone therapy in children with membranoproliferative glomerulonephritis. Acta Paediatr Jpn 1995;37:626-9.
84. Bahat E, Akkaya BK, Akman S, Karpuzoglu G, Guven AG. Comparison of pulse and oral steroid in childhood membranoproliferative glomerulonephritis. J Nephrol 2007;20:234-45.
85. Bergstein JM, Andreoli SP. Response of type I membranoproliferative glomerulonephritis to pulse methylprednisolone and alternate-day prednisone therapy. Pediatr Nephrol 1995;9:268-71.
86. Chapman SJ, Cameron JS, Chantler C, Turner D. Treatment of mesangiocapillary glomerulonephritis in children with combined immunosuppression and anticoagulation. Arch Dis Child 1980;55:446-51.
87. Faedda R, Satta A, Tanda F, Pirisi M, Bartoli E. Immunosuppressive treatment of membranoproliferative glomerulonephritis. Nephron 1994;67:59-65.
88. Choi MJ, Eustace JA, Gimenez LF, et al. Mycophenolate mofetil treatment for primary glomerular diseases. Kidney Int 2002;61:1098-114.
89. Bayazit AK, Noyan A, Cengiz N, Anarat A. Mycophenolate mofetil in children with multidrug-resistant nephrotic syndrome. Clin Nephrol 2004;61:25-9.
90. Jones G, Juszczak M, Kingdon E, Harber M, Sweny P, Burns A. Treatment of idiopathic membranoproliferative glomerulonephritis with mycophenolate mofetil and steroids. Nephrol Dial Transplant 2004;19:3160-4.
91. Guiard E, Karras A, Plaisier E, et al. Patterns of noncryoglobulinemic glomerulonephritis with monoclonal Ig deposits: correlation with IgG subclass and response to rituximab. Clin J Am Soc Nephrol 2011;6:1609-16.
92. Cameron JS, Turner DR, Heaton J, et al. Idiopathic mesangiocapillary glomerulonephritis: comparison of types I and II in children and adults and long-term prognosis. Am J Med 1983;74:175-92.
93. D'Amico G, Ferrario F. Mesangiocapillary glomerulonephritis. J Am Soc Nephrol 1992;2:Suppl:S159-S166.
94. Nester C, Stewart Z, Myers D, et al. Pre-emptive eculizumab and plasmapheresis for renal transplant in atypical hemolytic uremic syndrome. Clin J Am Soc Nephrol 2011;6:1488-94.
95. Lapeyraque A-L, Frémeaux-Bacchi V, Robitaille P. Efficacy of eculizumab in a patient with factor-H-associated atypical hemolytic uremic syndrome. Pediatr Nephrol 2011;26:621-4.
96. Gruppo RA, Rother RP. Eculizumab for congenital atypical hemolytic–uremic syndrome. N Engl J Med 2009;360:544-6.
97. Licht C, Weyersberg A, Heinen S, et al. Successful plasma therapy for atypical hemolytic uremic syndrome caused by factor H deficiency owing to a novel mutation in the complement cofactor protein domain 15. Am J Kidney Dis 2005;45:415-21.
98. Andresdottir MB, Assmann KJM, Hoitsma AJ, Koene RAP, Wetzels JFM. Recurrence of type I membranoproliferative glomerulonephritis after renal transplantation: analysis of the incidence, risk factors, and impact on graft survival. Transplantation 1997;63:1628-33.
99. Karakayali FY, Ozdemir H, Kivrakdal S, Colak T, Emiroğlu R, Haberal M. Recurrent glomerular diseases after renal transplantation. Transplant Proc 2006;38: 470-2.
100. Lorenz EC, Sethi S, Leung N, Dispenzieri A, Fervenza FC, Cosio FG. Recurrent membranoproliferative glomerulonephritis after kidney transplantation. Kidney Int 2010;77:721-8.

Copyright © 2012 Massachusetts Medical Society.

NEJM 200TH ANNIVERSARY AND SOCIAL MEDIA

Follow NEJMTeam on Twitter and click "Like" on the *New England Journal of Medicine* page on Facebook for links to the latest articles, stories, and multimedia available at the NEJM 200th Anniversary website, http://NEJM200.NEJM.org. Tweets incorporating the hashtag #NEJM200 also appear in a Twitter feed at the anniversary website.

The New England Journal of Medicine
Downloaded from nejm.org by LUIGI GRECO on April 16, 2012. For personal use only. No other uses without permission.
Copyright © 2012 Massachusetts Medical Society. All rights reserved.